

Tumoren des hinteren Augenabschnitts

Herkunftsgewebe

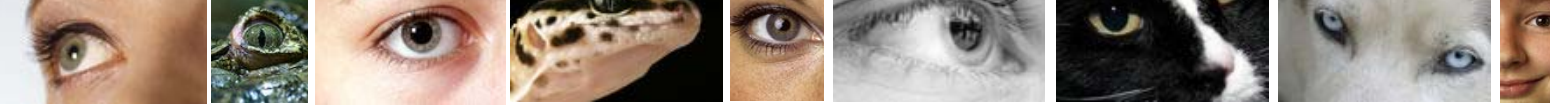
Netzhaut

Aderhaut

Dignität

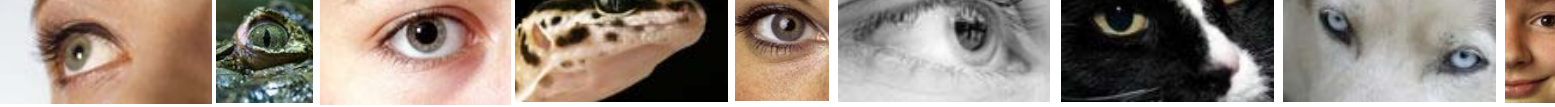
benigne

maligne

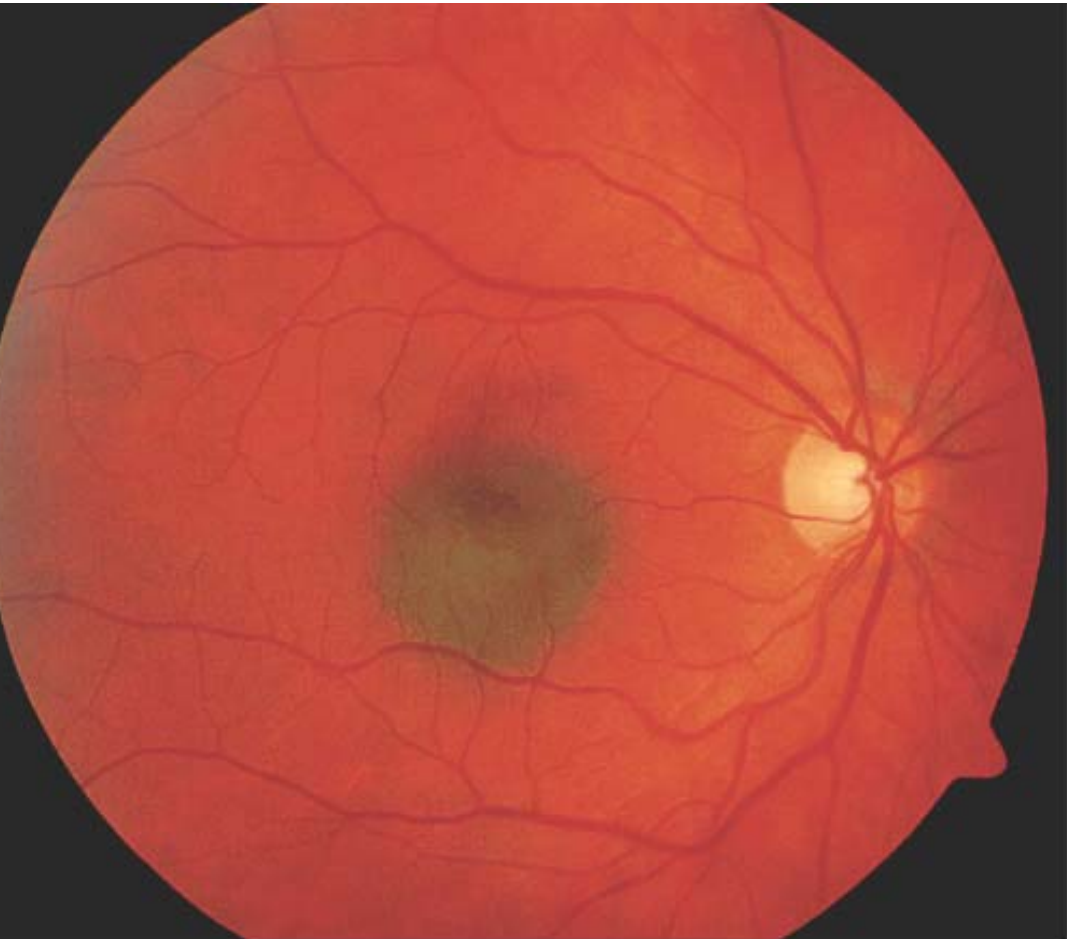

Symptome

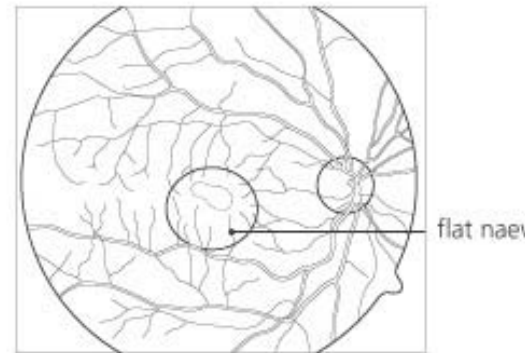
- Keine (90 %)
- Sehverschlechterung (manchmal)
- Schmerzen (extrem selten)
- Schielen (selten)
- Größenänderungen des Auges (selten)
- Farbänderungen des Auges (selten)

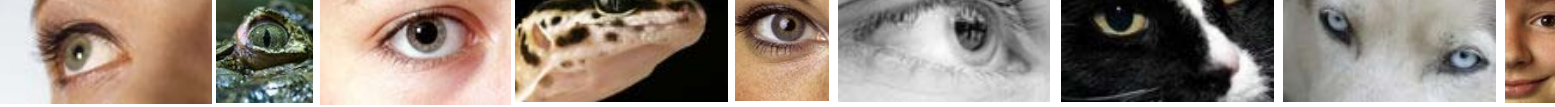


Aderhautnävus

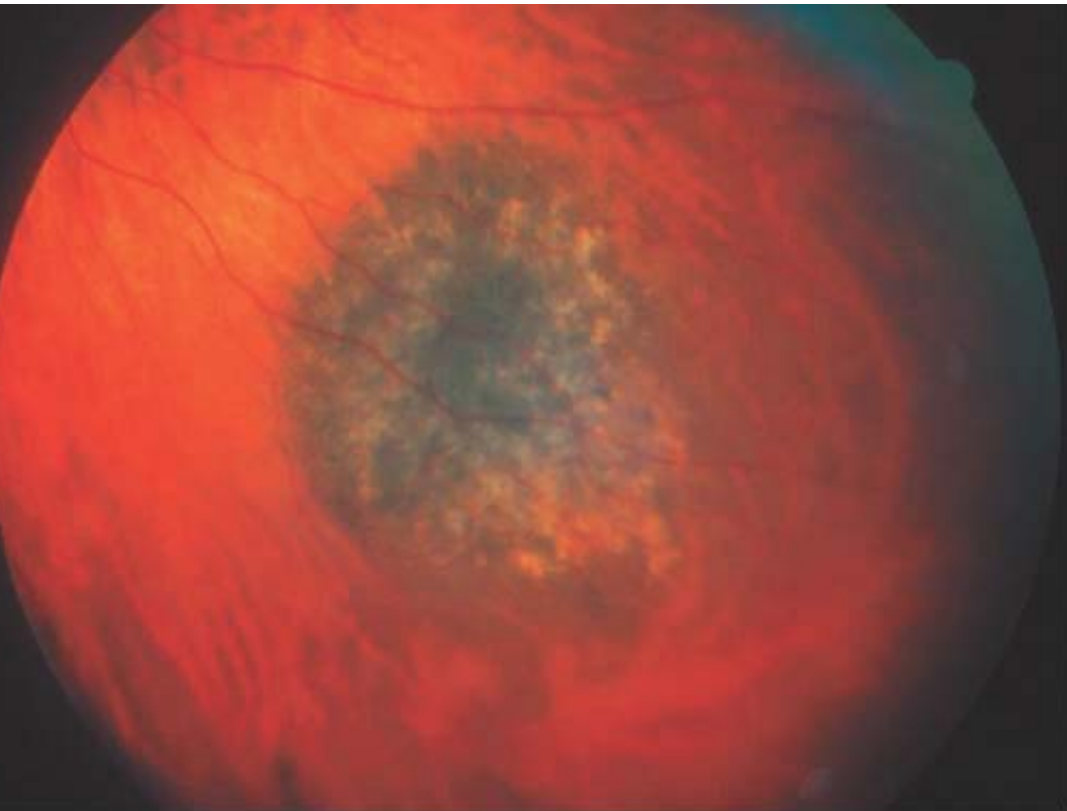


ca. 10 % aller Augen
Risiko für maligne Entartung
1/50.000 in 10 Jahren

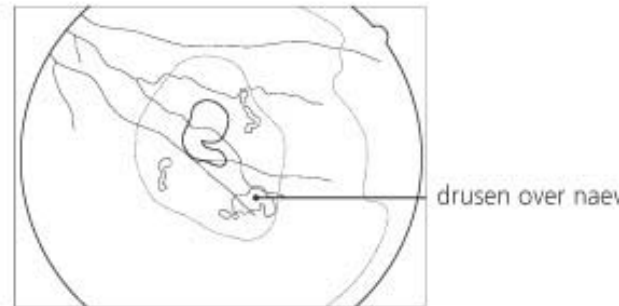


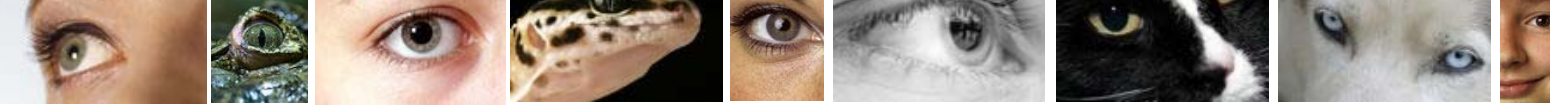


Aderhautnävus

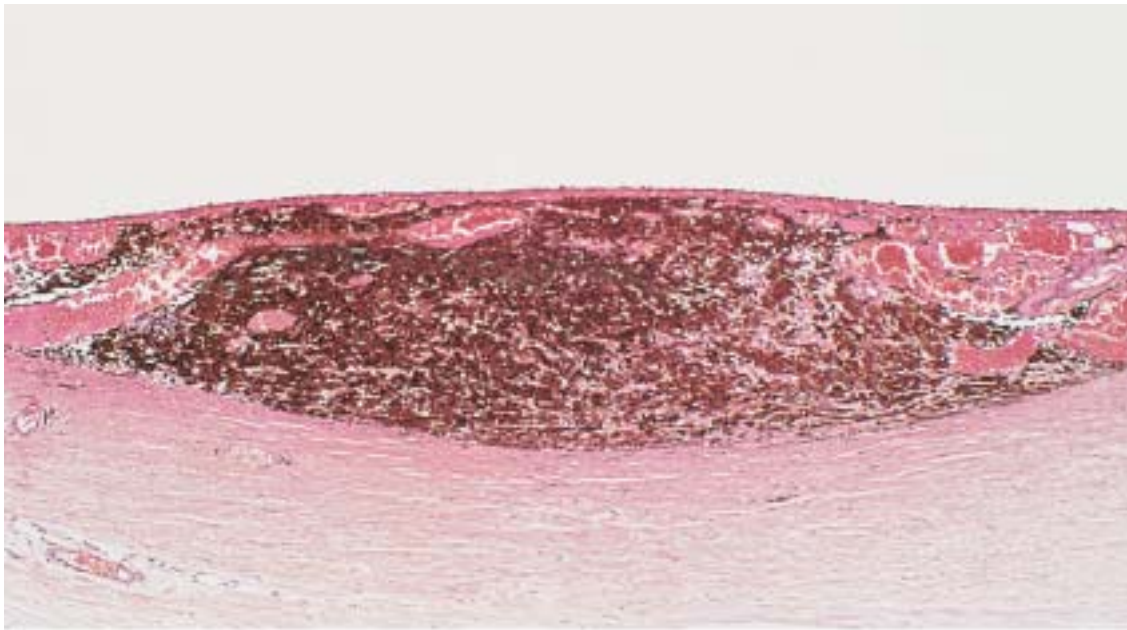


Therapie:
Kontrolle
Fotodokumentation
Cave: Größenwachstum

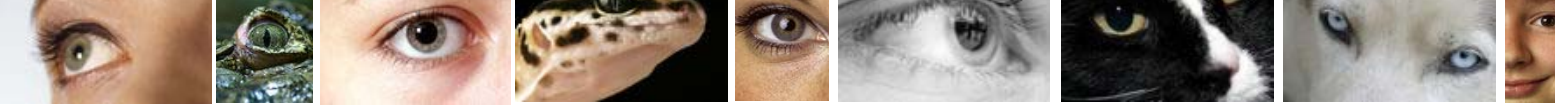




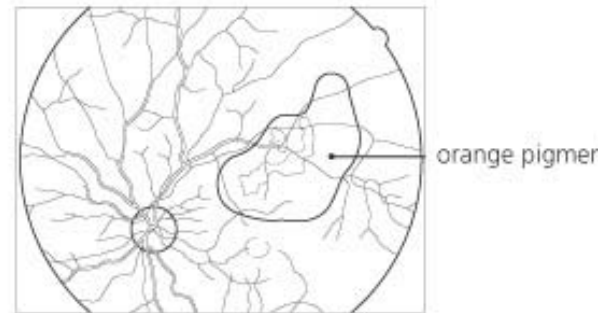
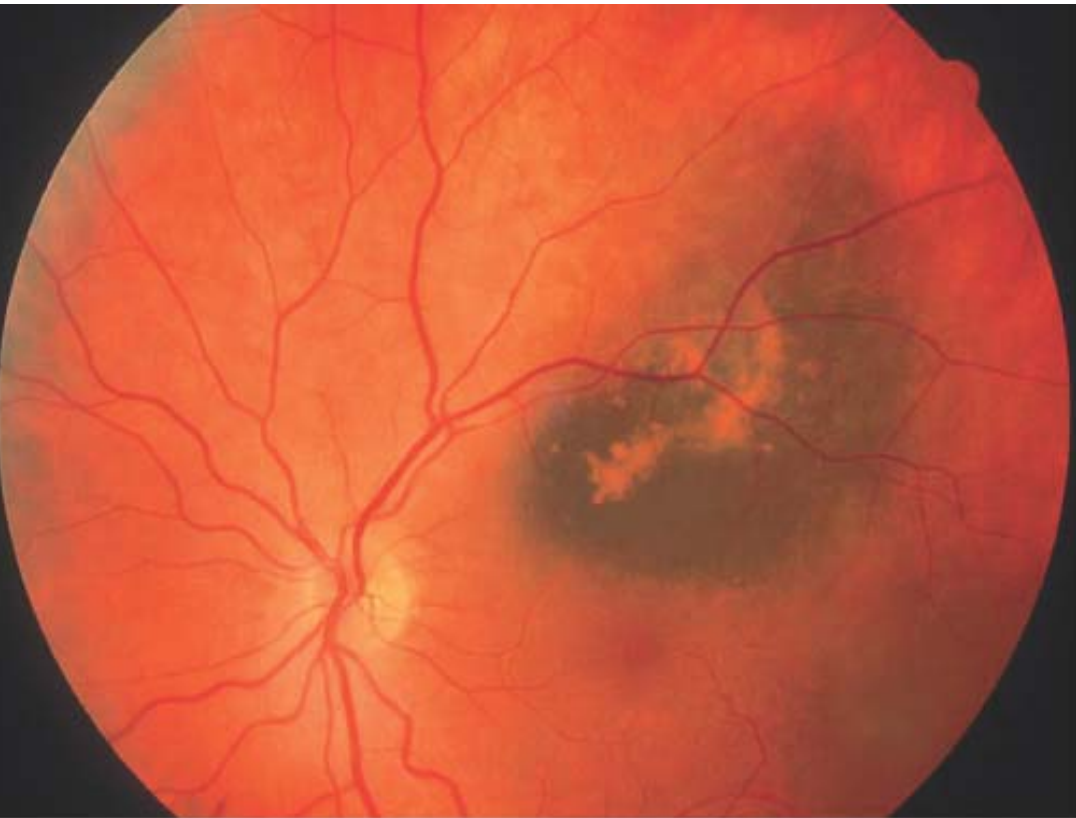
Aderhautnävus: Histopathologie

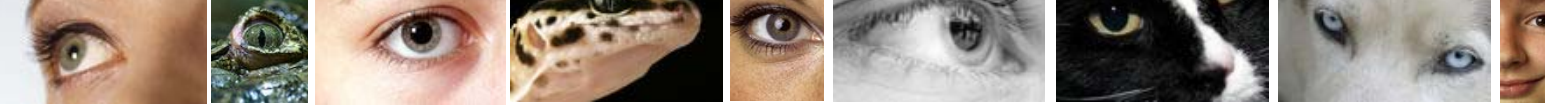


© 2005 Elsevier Ltd. Spalton et al: Atlas of Clinical Ophthalmology 3e



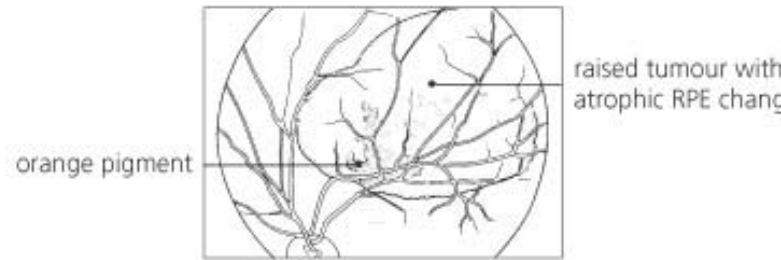
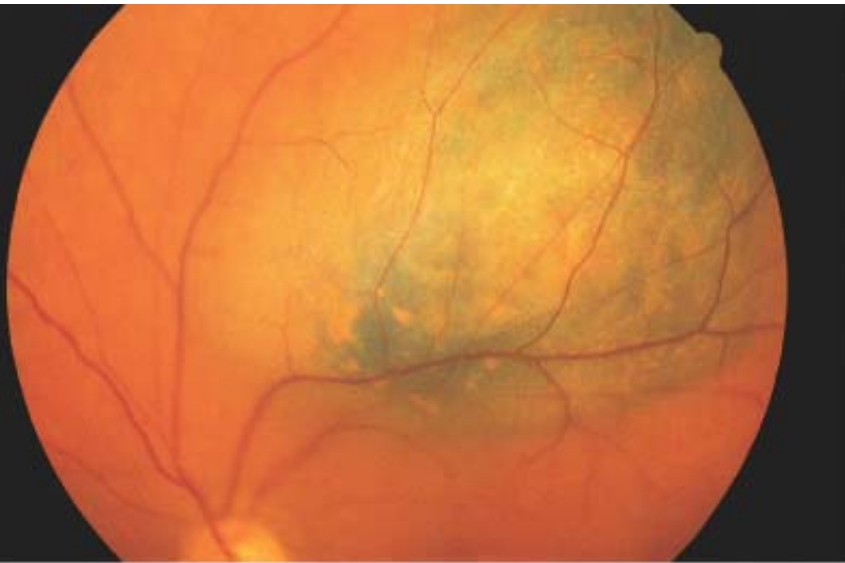Aderhautnävus: „orange pigment“

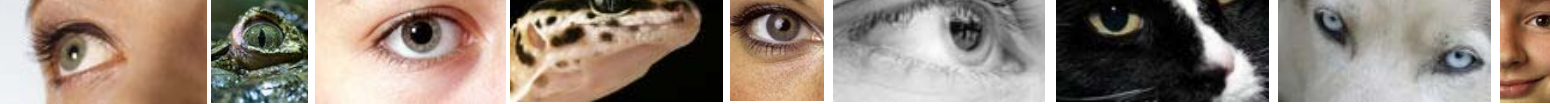




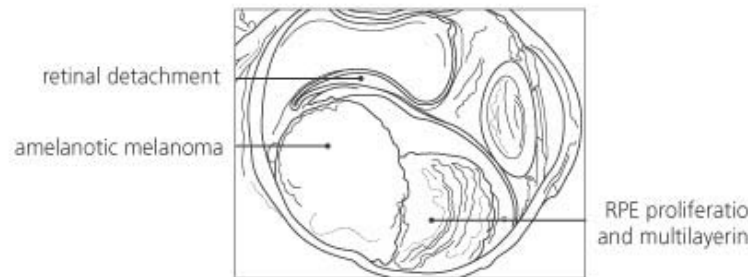
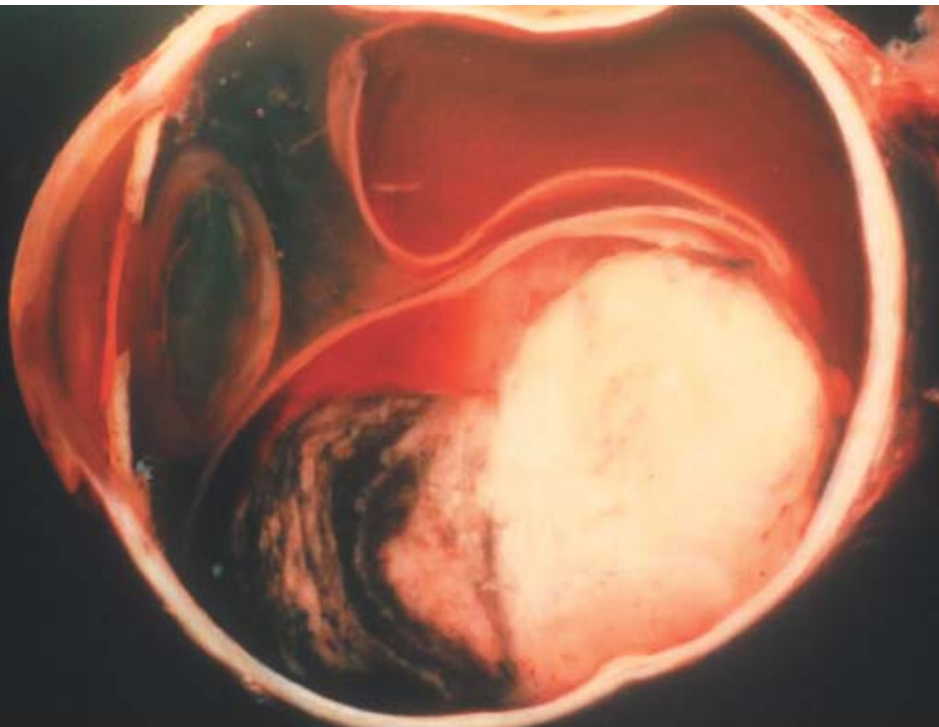
Aderhautnävus oder Aderhautmelanom ?

Prominenz ? Wachstum ?

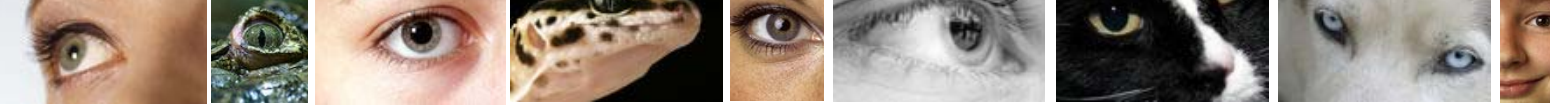




Aderhautmelanom: amelanotisch Begleitamotio, RPE Proliferation

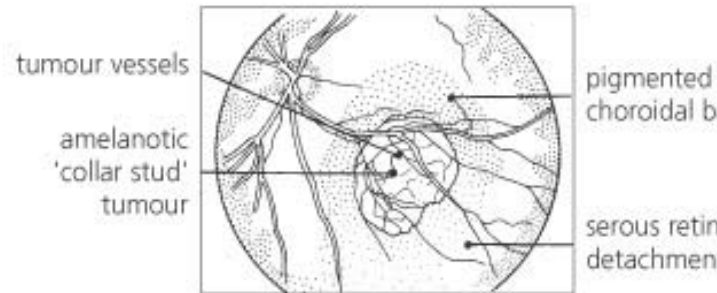
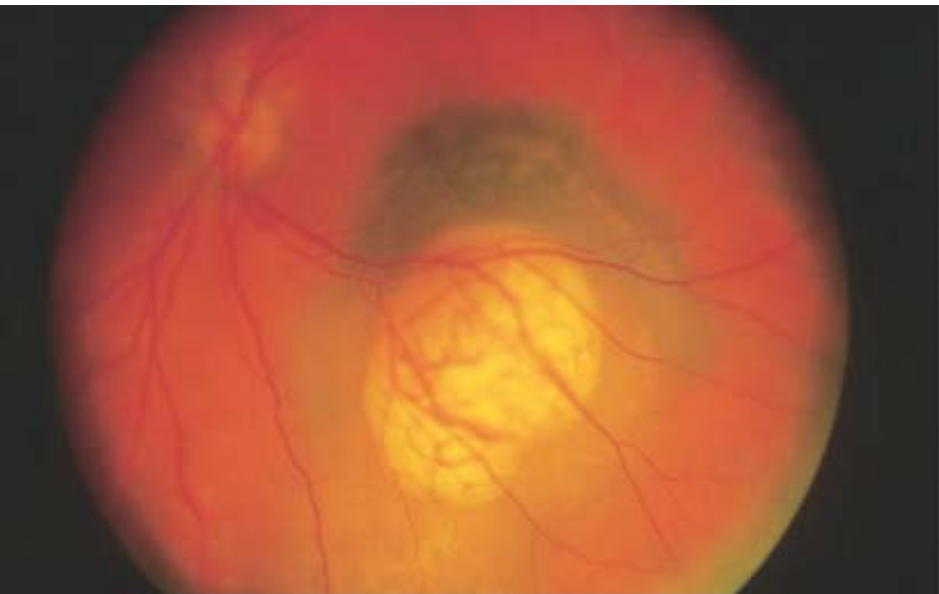

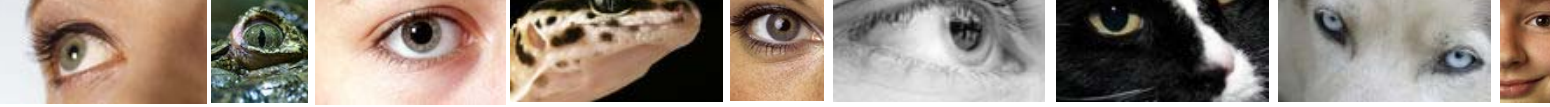
Inzidenz: 0.8 / 10.000 / Jahr
5 Jahresüberlebensrate: 75 %
Metastasen: Leber, Lunge



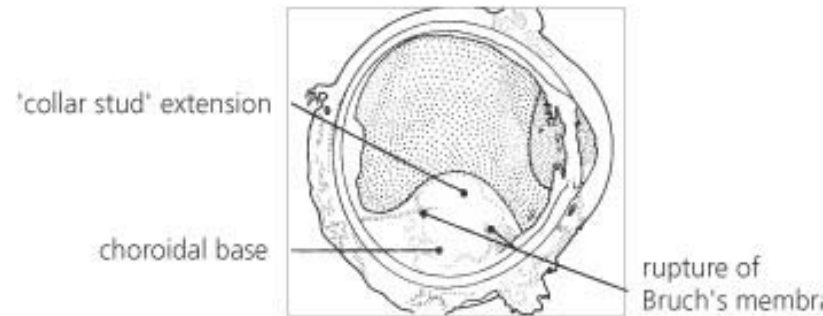
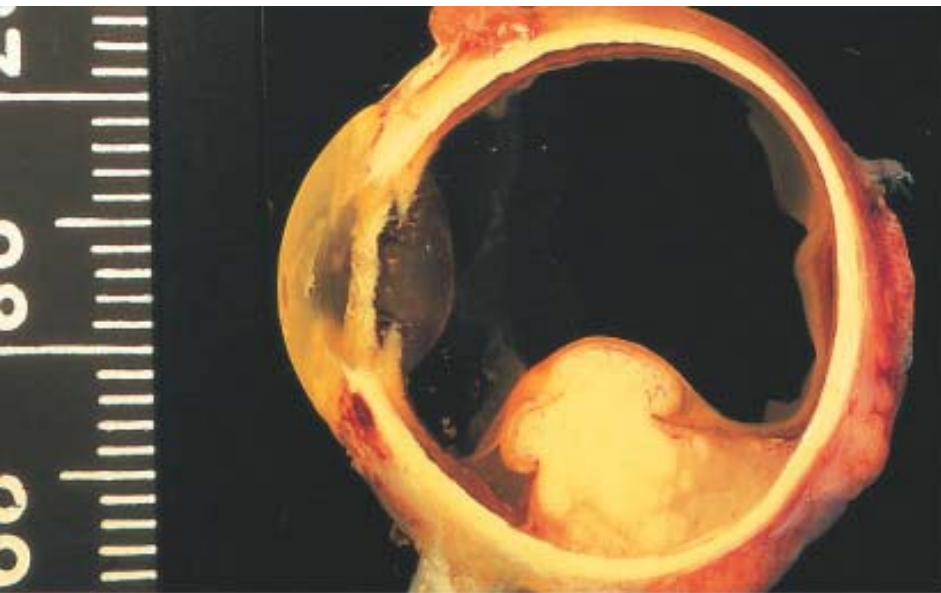
Aderhautmelanom

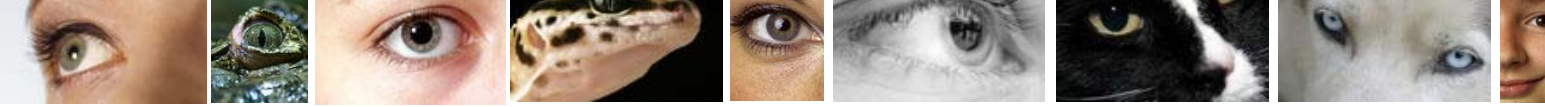
Ätiologische Faktoren:
Nävus, okuläre Melanose
Dysplastisches Nävussyndrom
Neurofibromatose
Chromosemanomalien



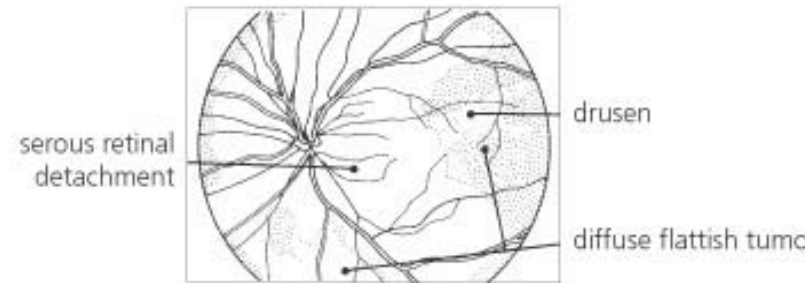
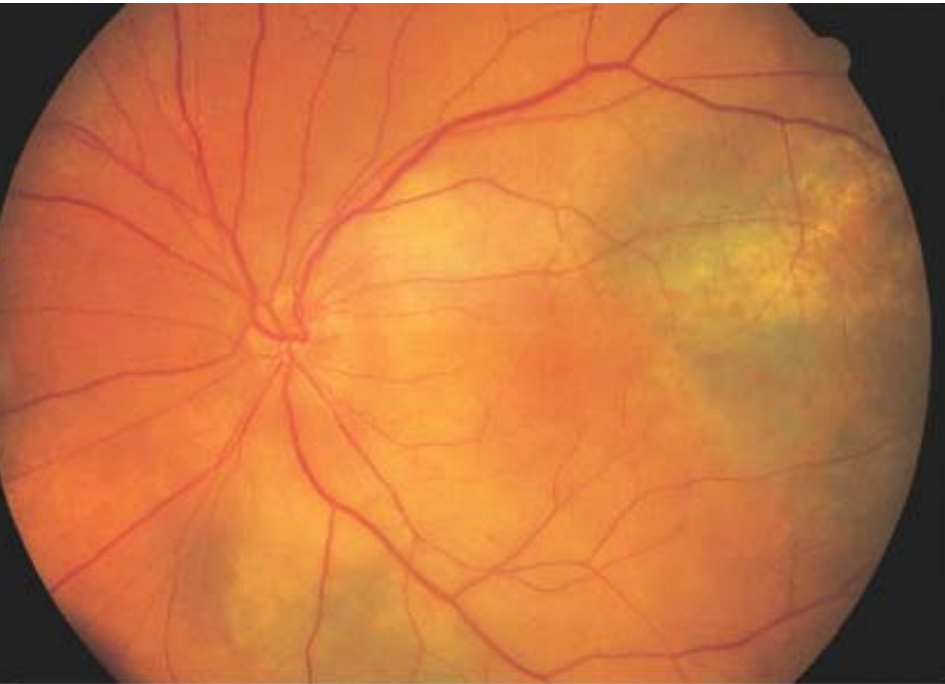


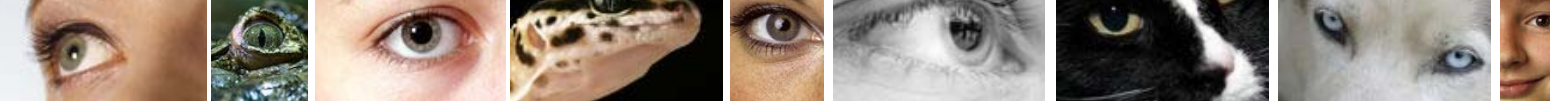Champignonkonfiguration nach Durchbrechen der Bruchschen Membran



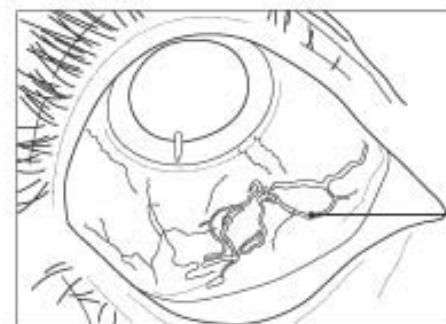
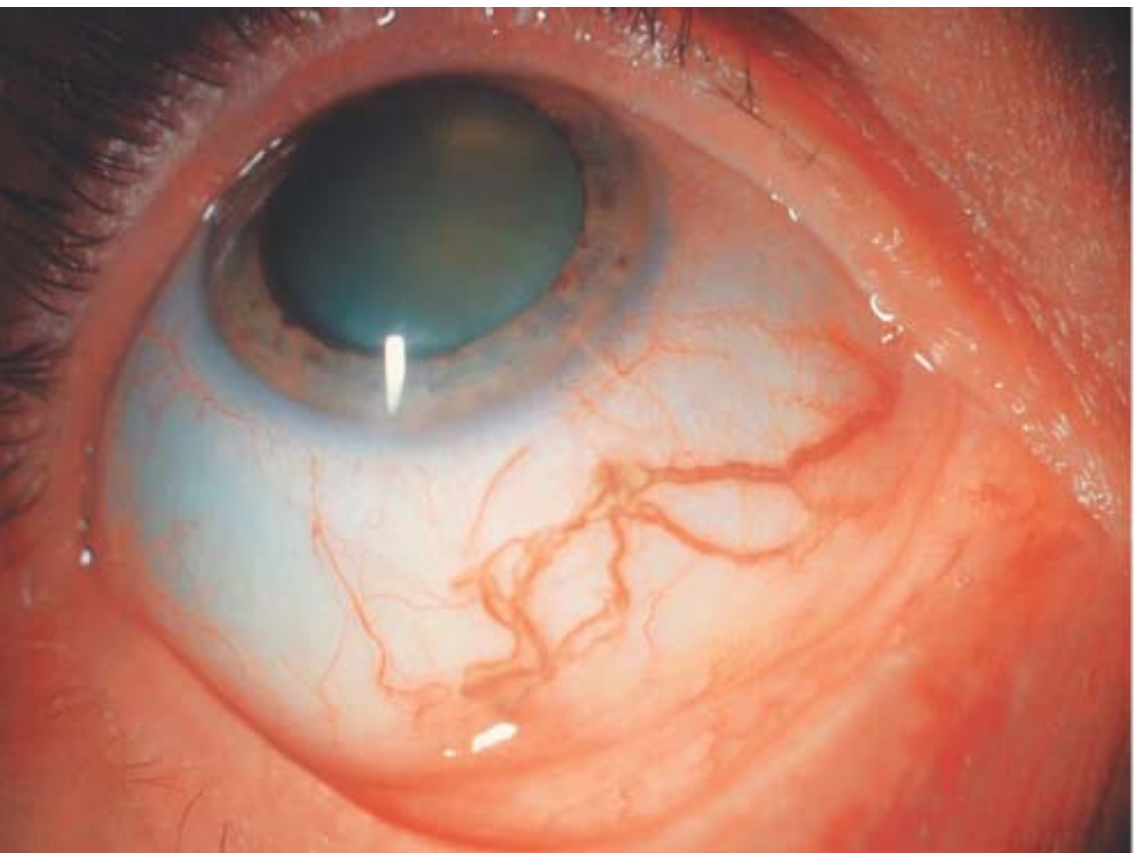

Seröse Netzhautablösung als Begleitzeichen beim Aderhautmelanom

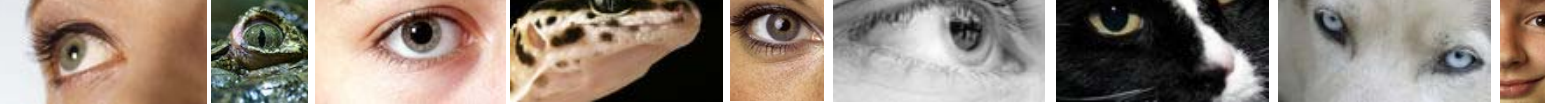




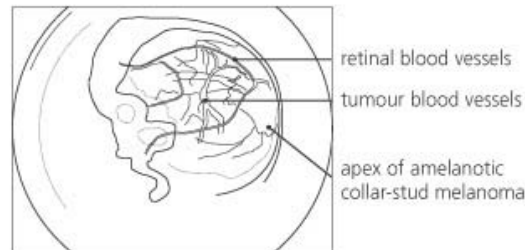
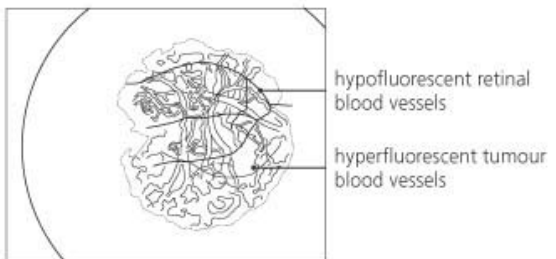
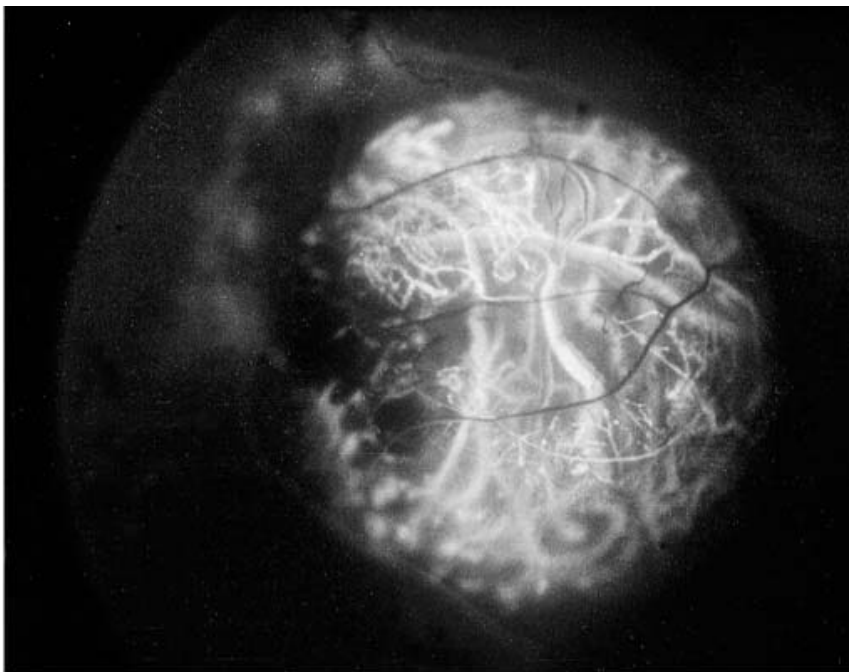
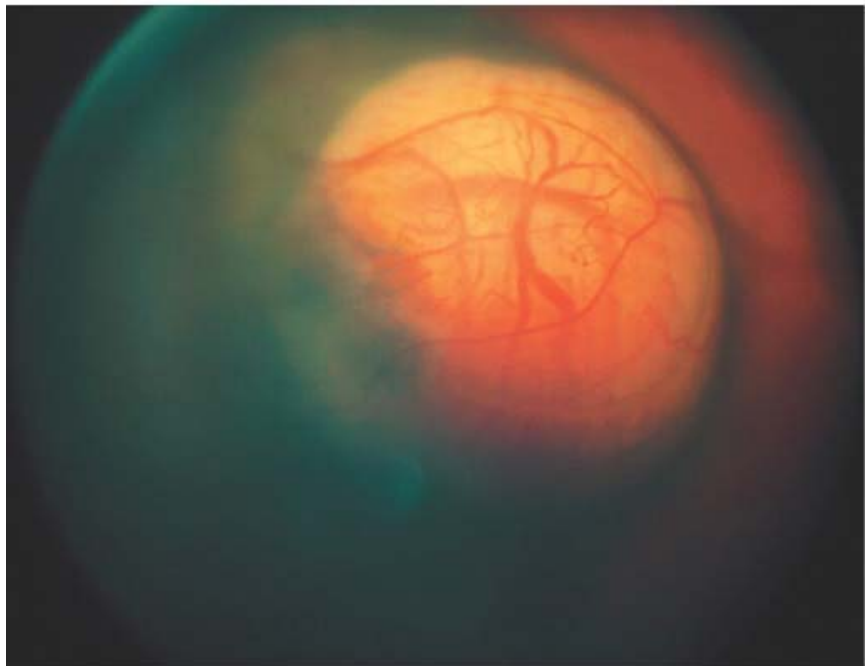
Dilatierte episklerale Gefäße als Begleitzeichen beim Aderhautmelanom

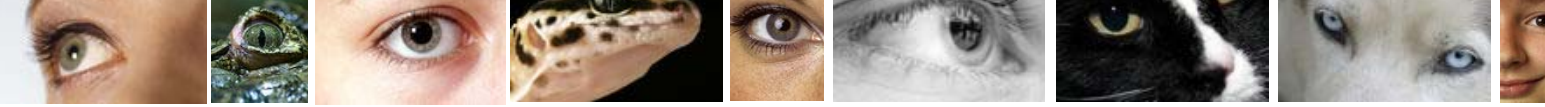


dilated ves

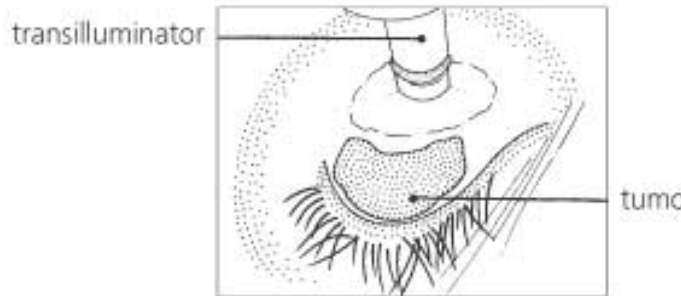



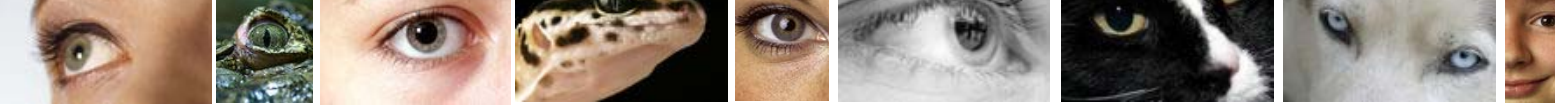
Tumoreigene Gefäße beim Aderhautmelanom



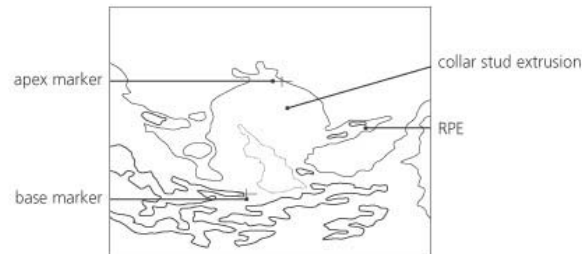
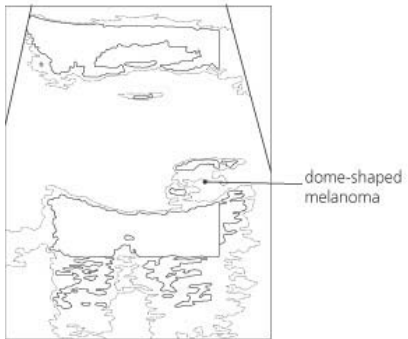
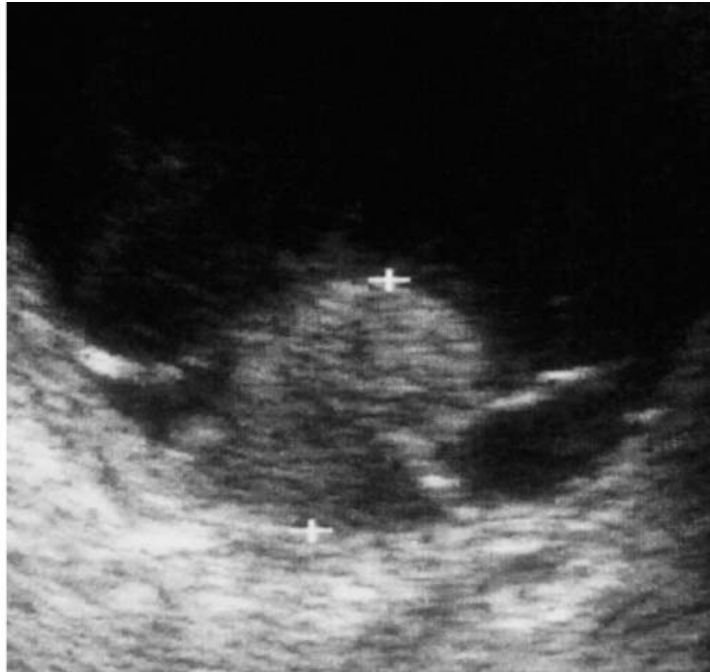
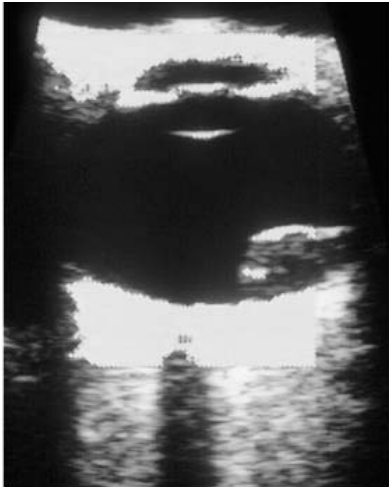
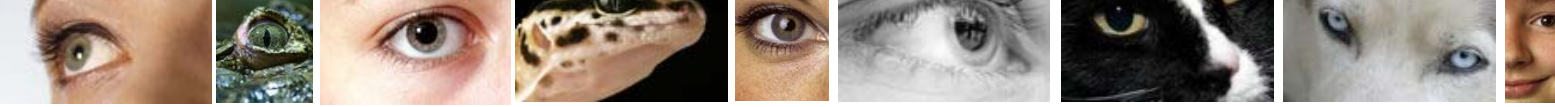
Diagnostik: Diaphanoskopie



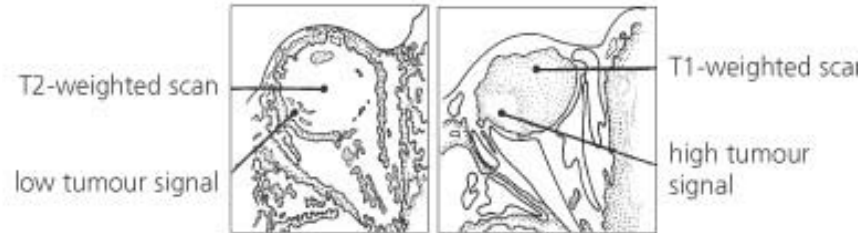
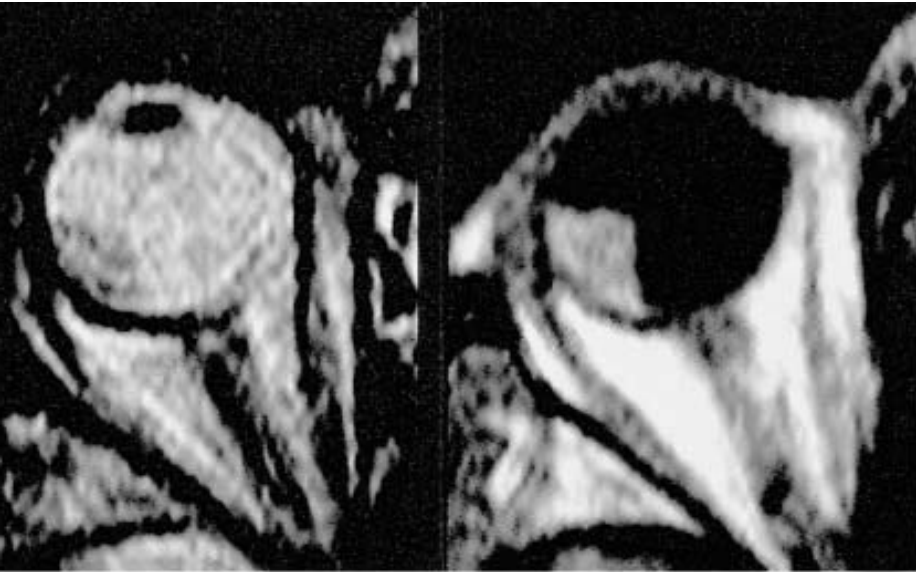


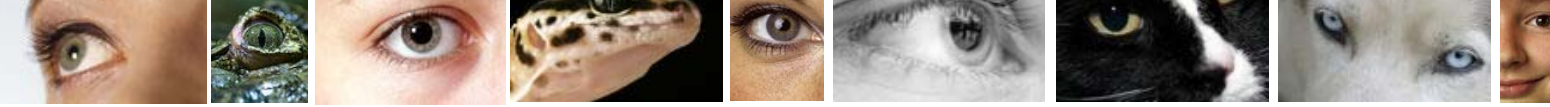
Diagnostik: Ultraschall





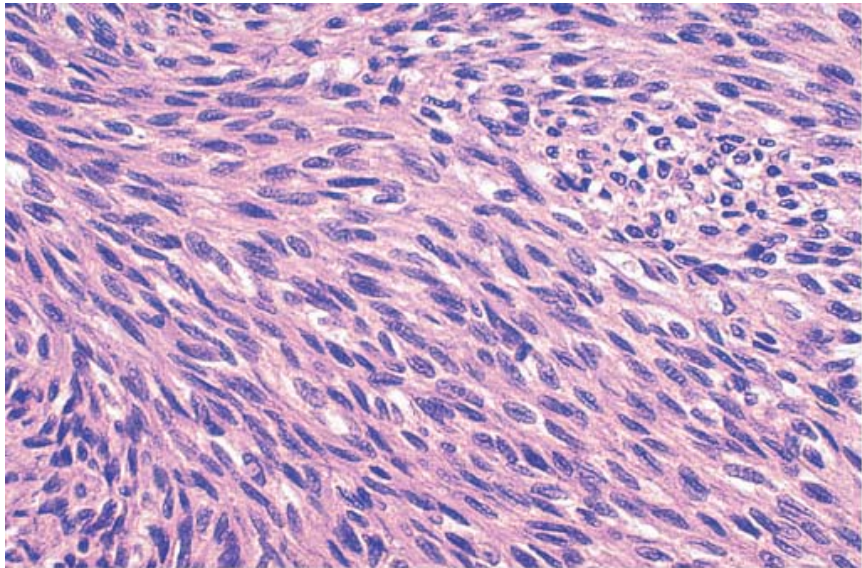
Diagnostik: CT, NMR



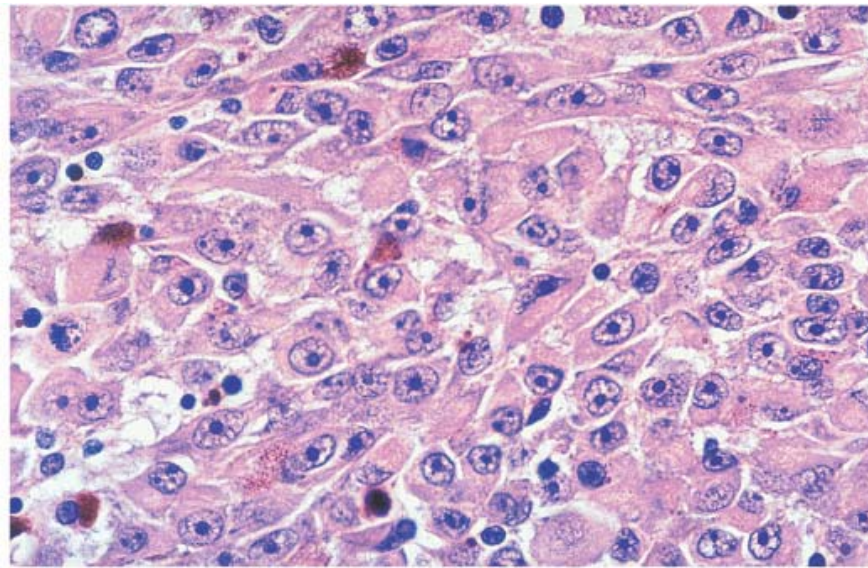


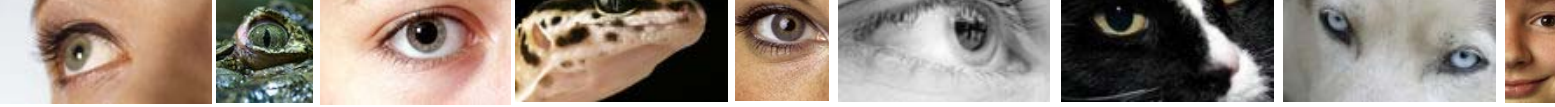
Aderhautmelanom: Histologie

Spindelzelltyp

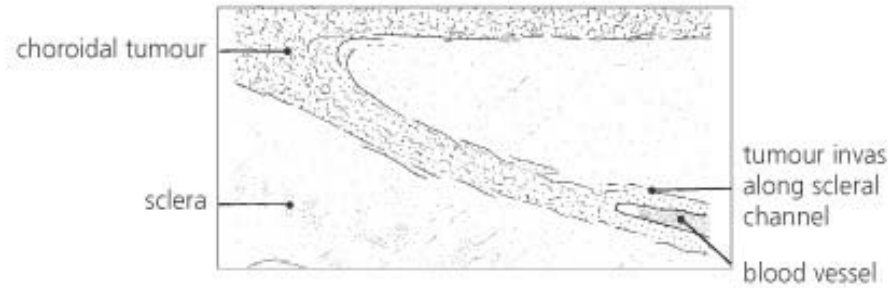
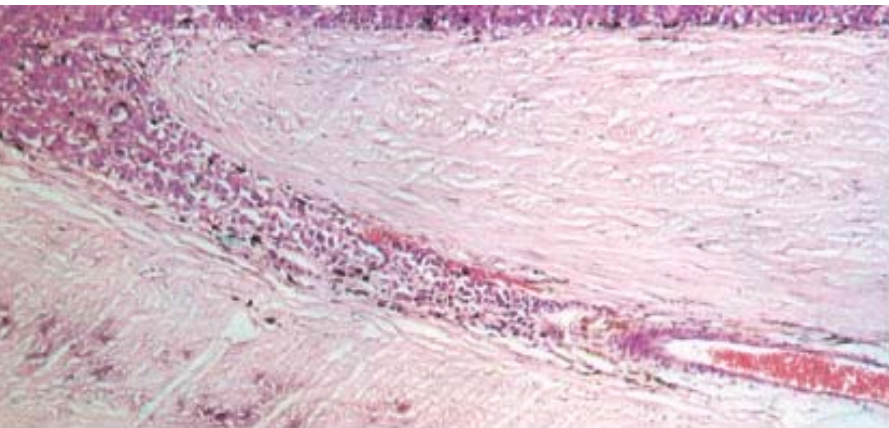


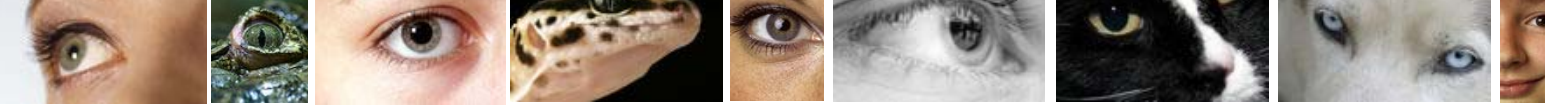
epitheloidzellig





Aderhautmelanom: Gefäßinvasion





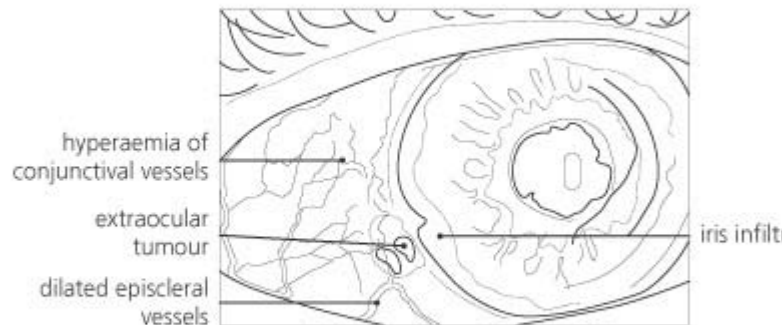
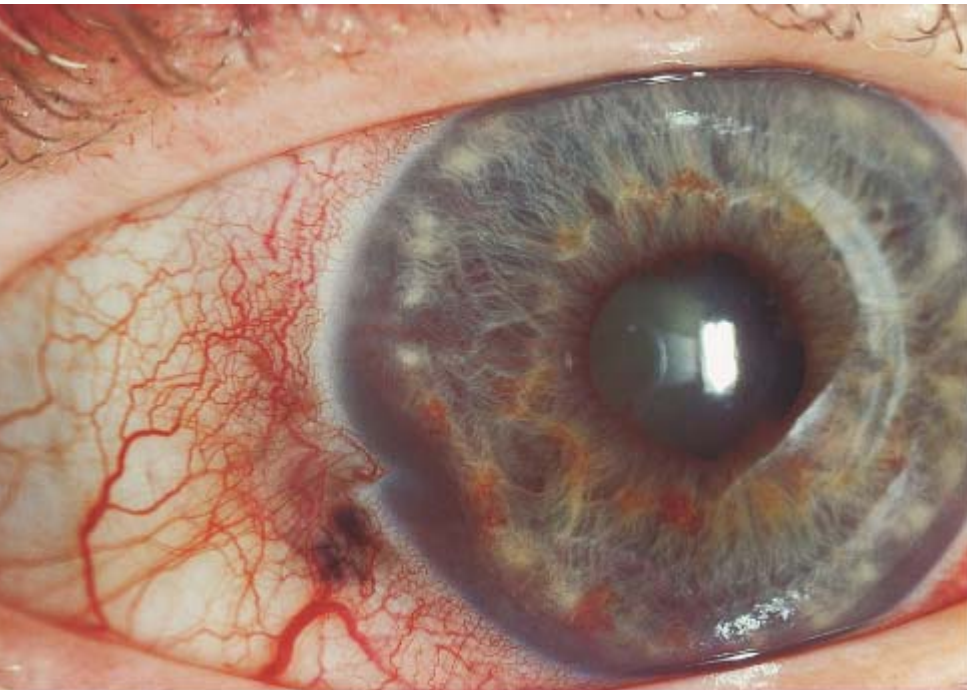
Skleradurchbruch !

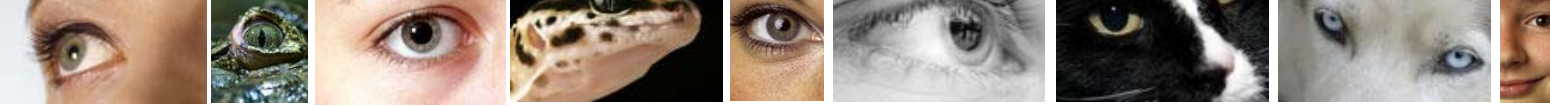
5 Jahresüberlebensrate: 40 - 80 %

Tumorgröße

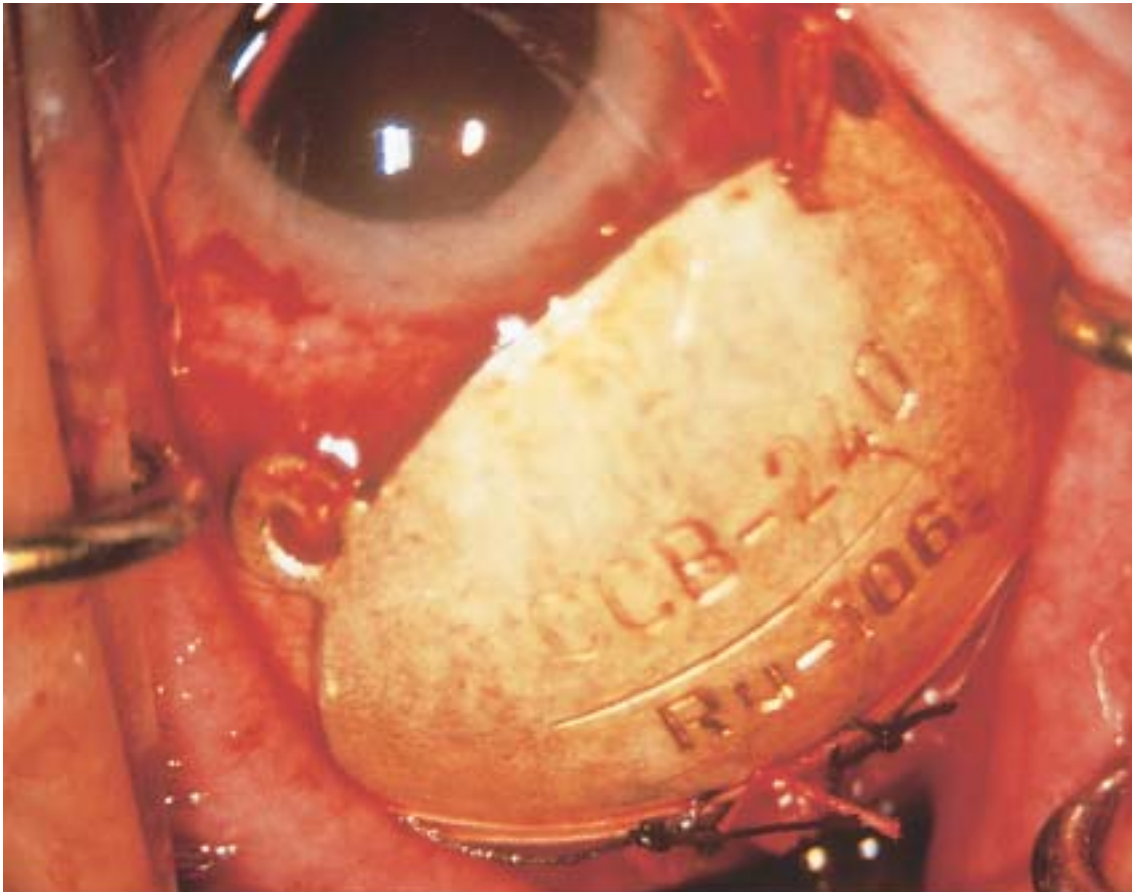
Histologie

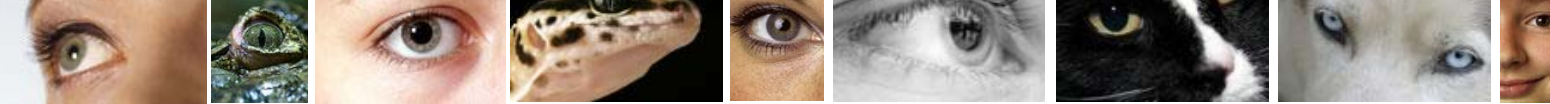
Chromosomale Abberation



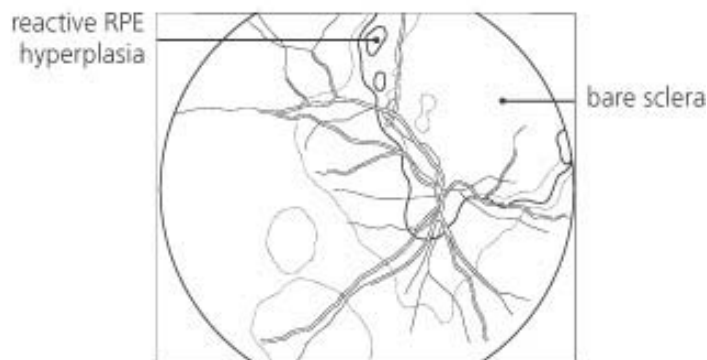
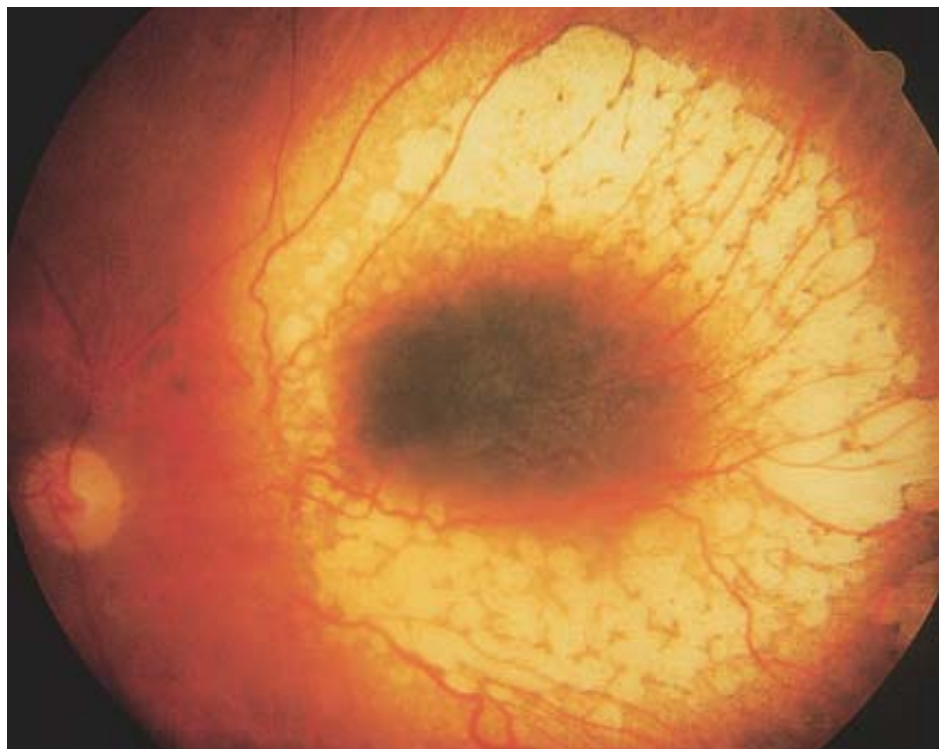

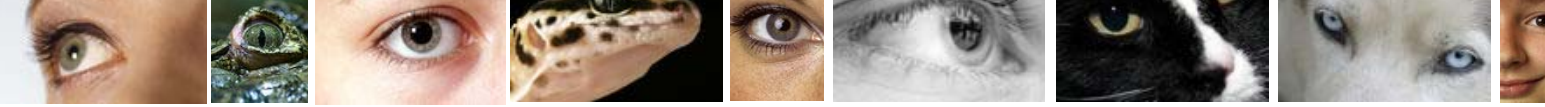
Therapieziel: Tumorkontrolle, hier Rutheniumbrachytherapi



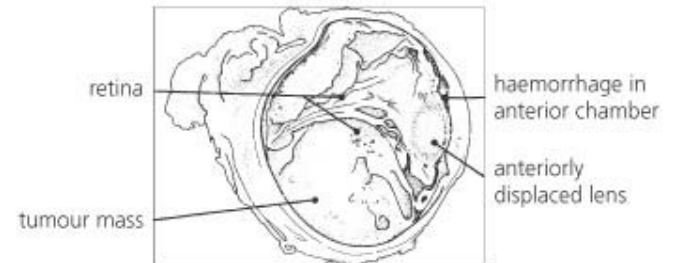
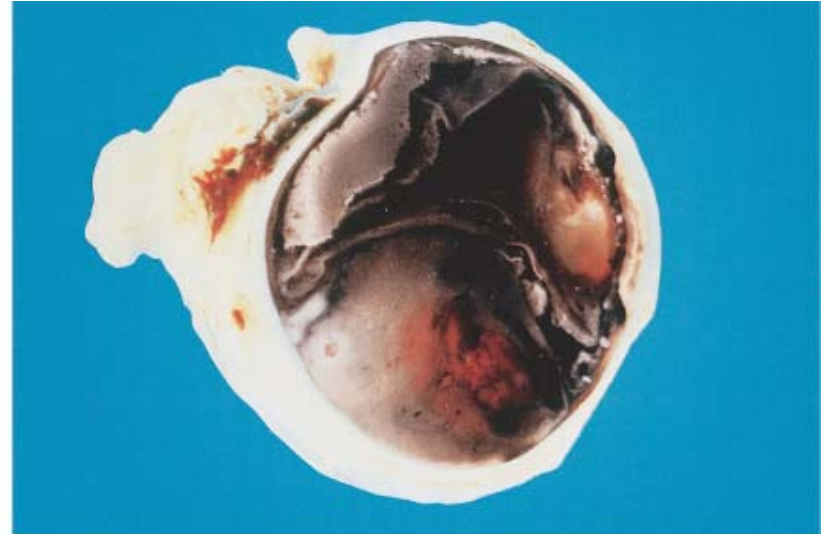
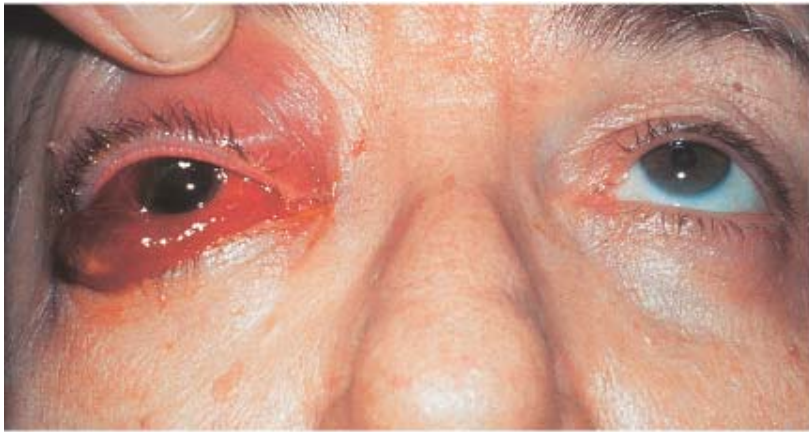

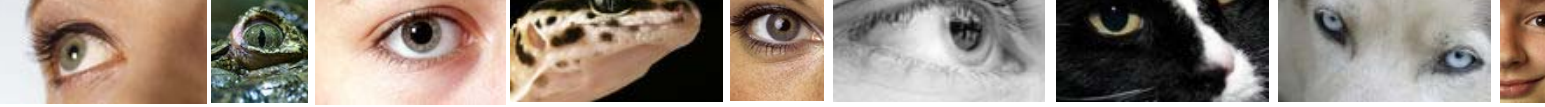
Ergebnis nach lokaler Tumorbestrahlung mit Ru 106





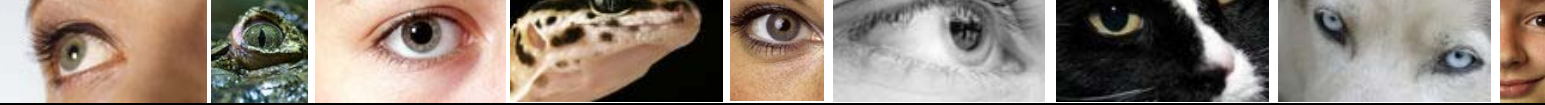
Enukleation



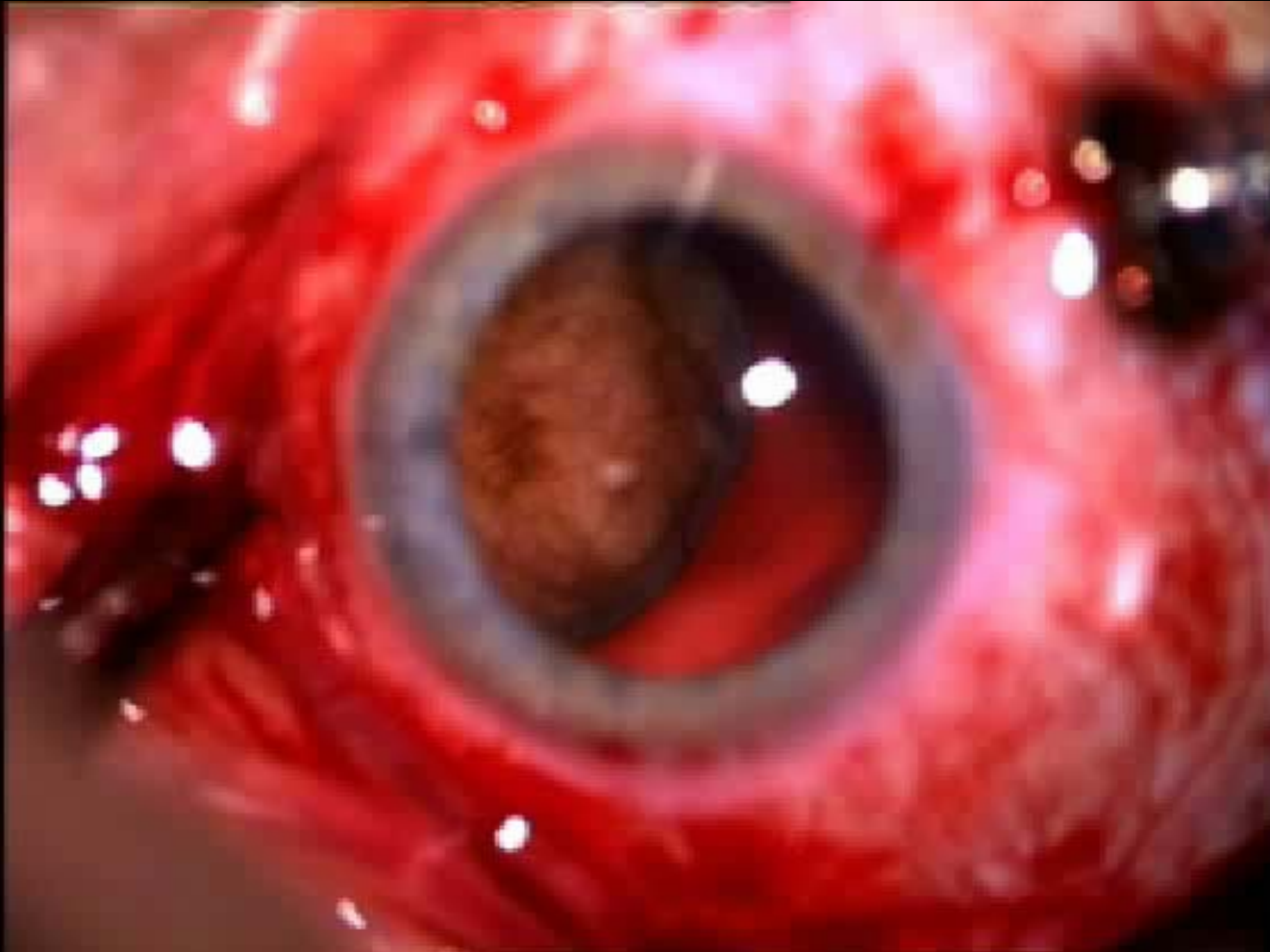


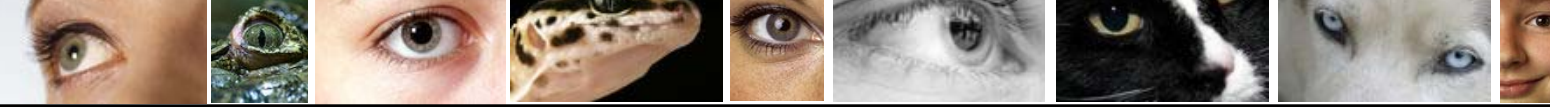
Therapieverfahren-Aderhautmelanom-Übersicht

- **Enukleation**
- **Endo- oder Exoresektion**
- **Brachytherapie (Ru plaque)**
- **Thermotherapie**
- **Protonenbestrahlung**
- **Gamma Knife**
- **Beobachtung ?**

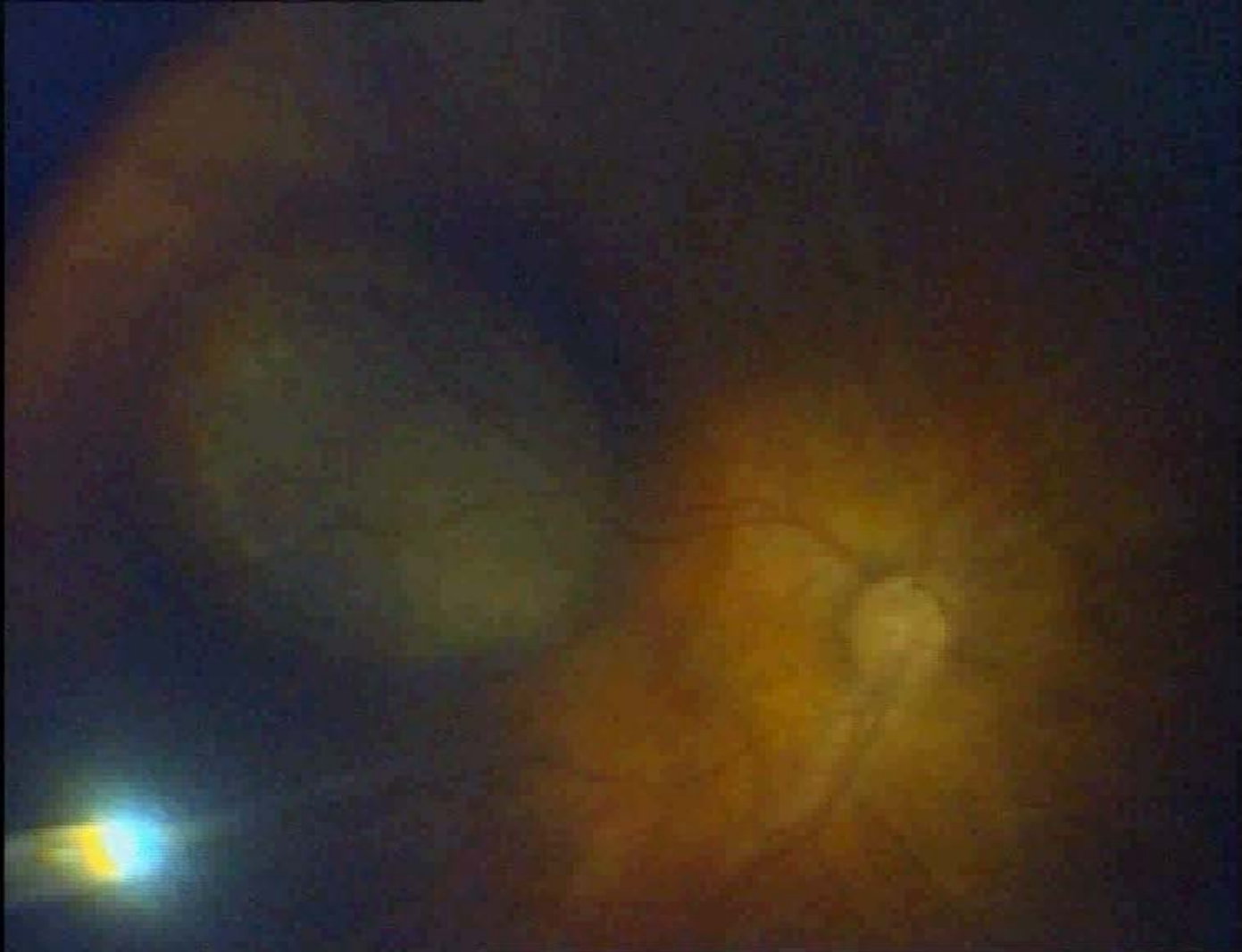

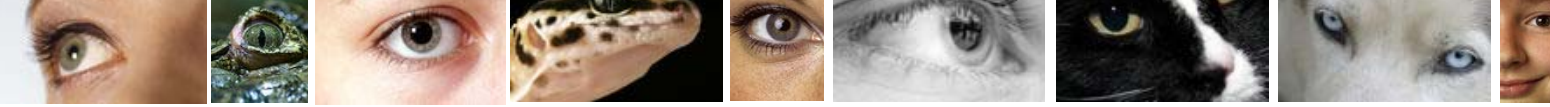
Bulbuserhaltende Resektionsverfahren 1: Exoresektion



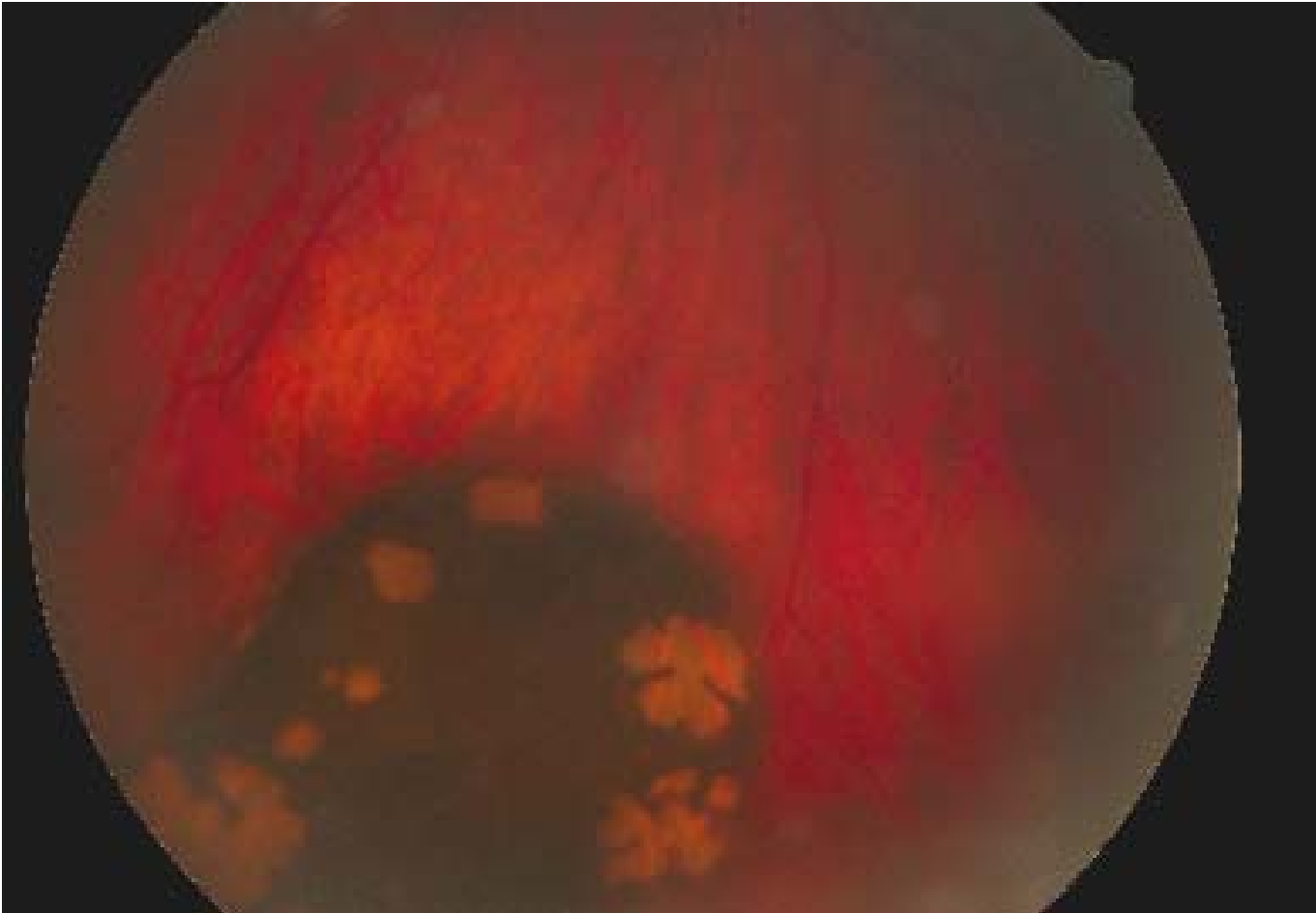


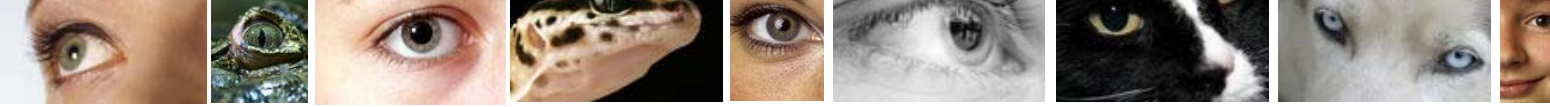
Bulbuserhaltende Resektionsverfahren 2: Endoresektion



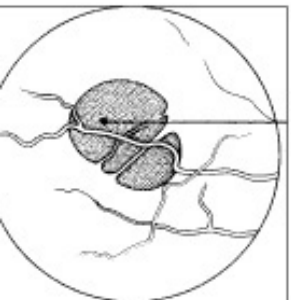
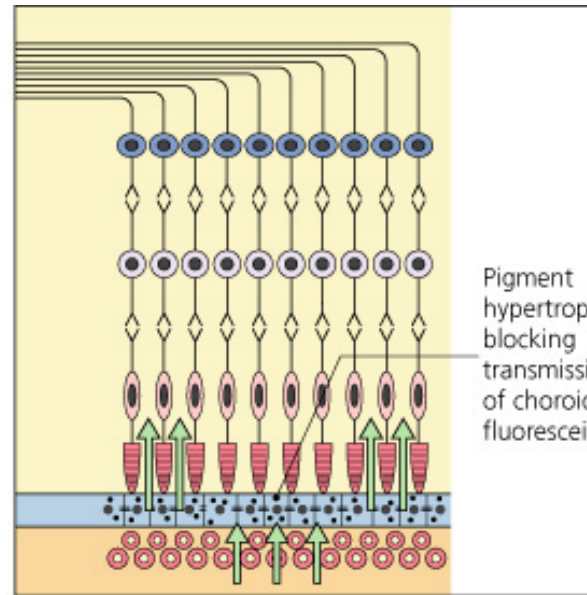
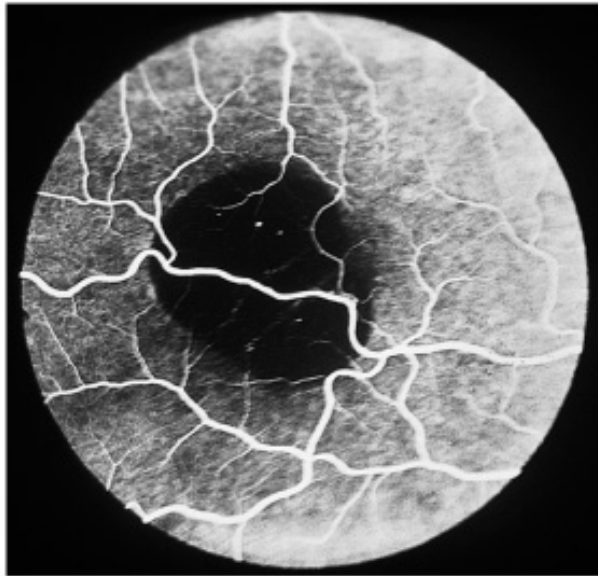
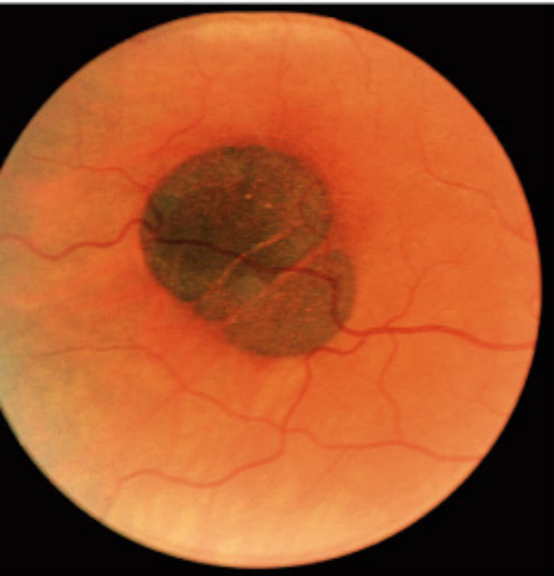
Differentialdiagnose Tumoren Pigmentepithelhyperplasie

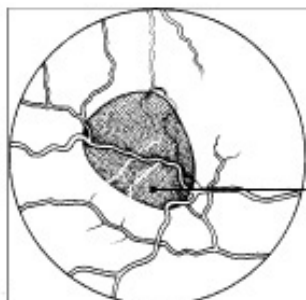




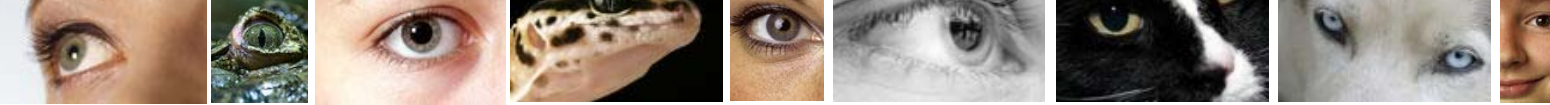
Pigmentepithelhypertrophie



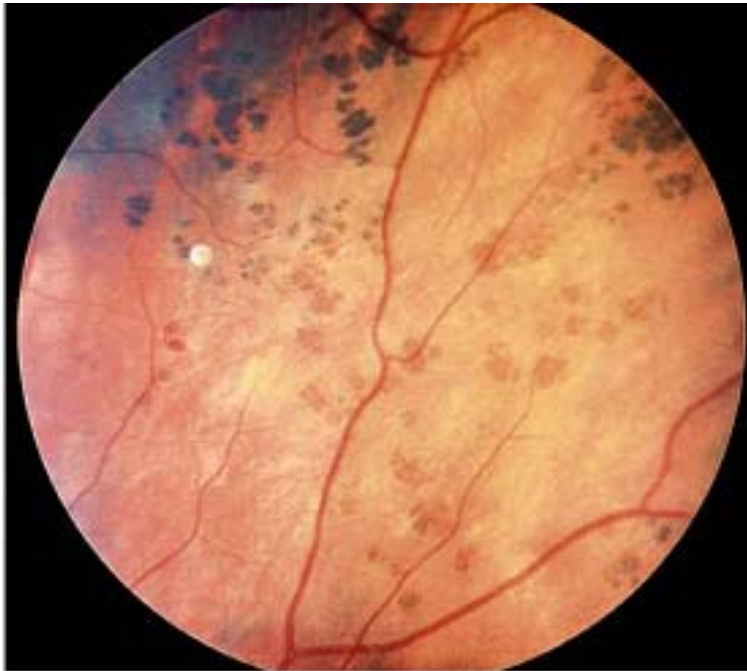
benign pigment epithelial hypertrophy



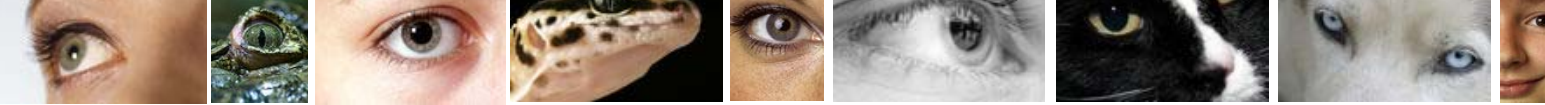
dense masking of choroidal fluorescence



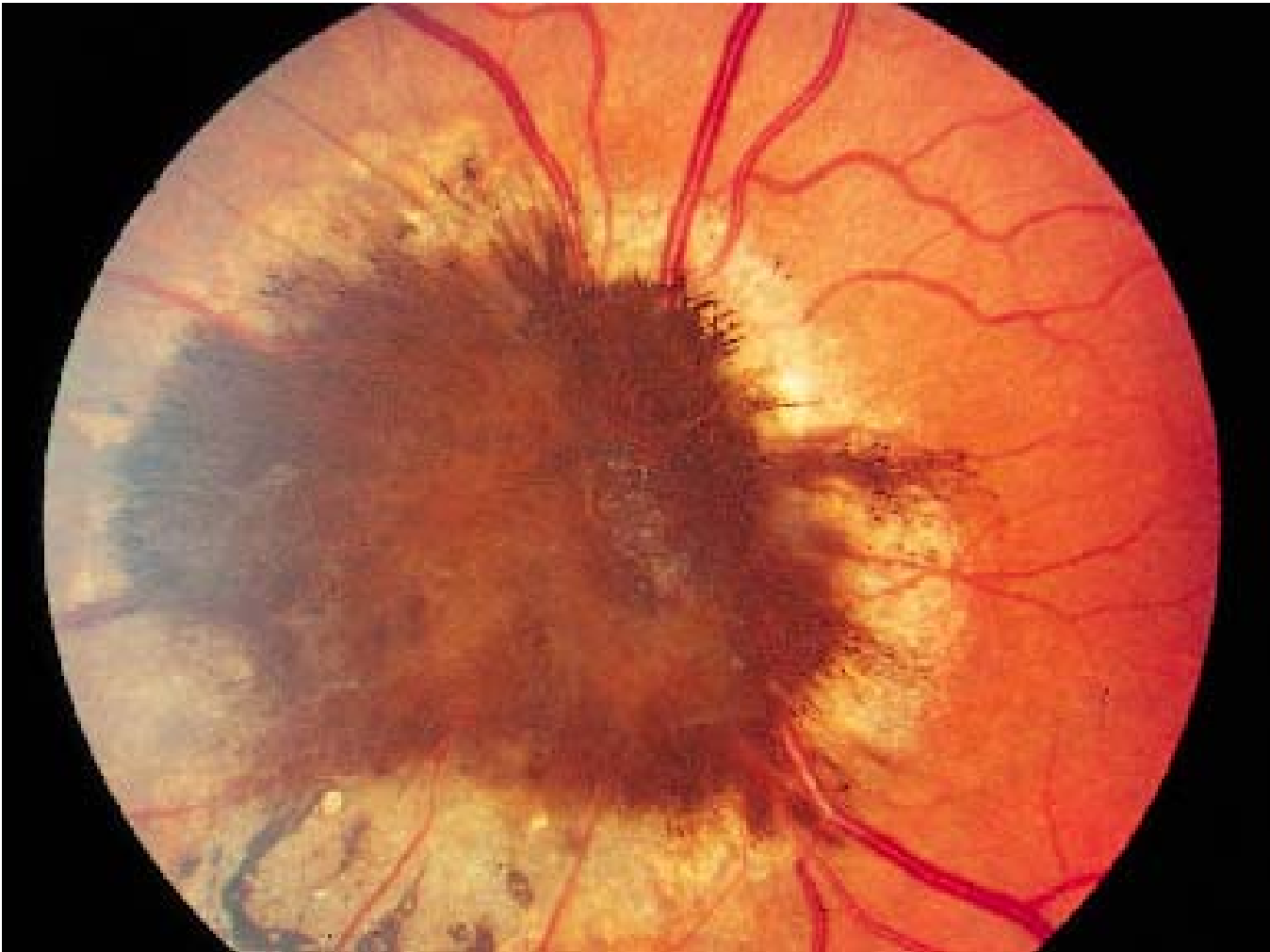
Pigmentepithelhypertrophie: „Bärentatzen“

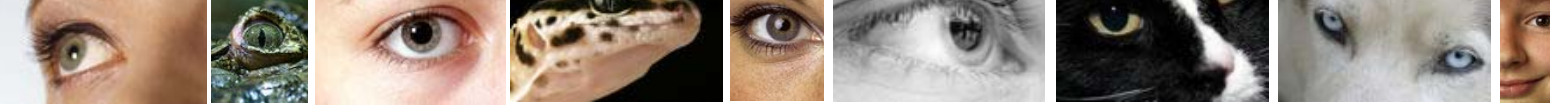


© 2005 Elsevier Ltd. Spalton et al: Atlas of Clinical Ophthalmology 3e

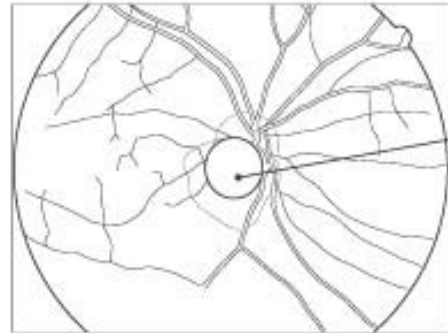
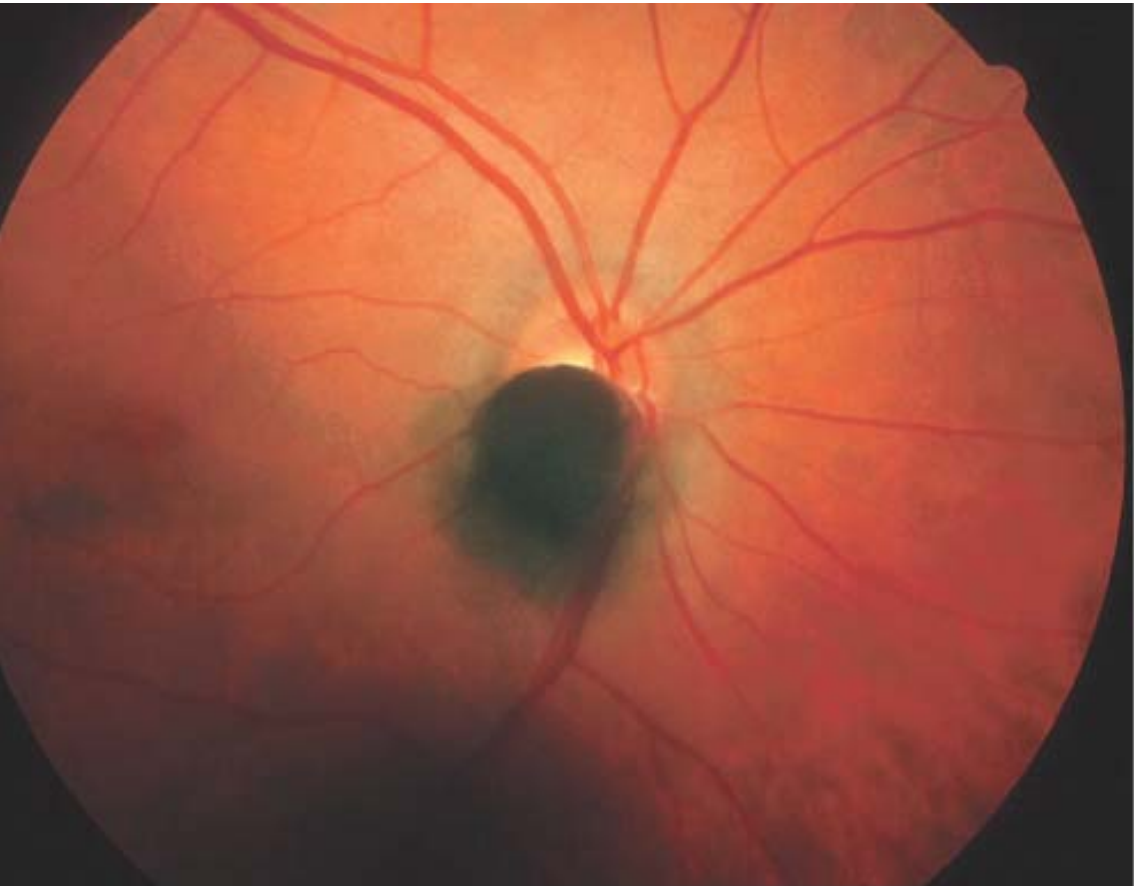


DD Aderhautmelanom: Melanozytom der Papille

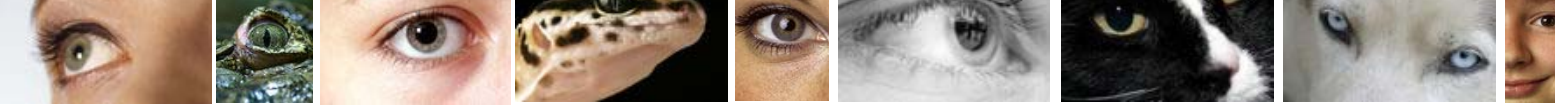




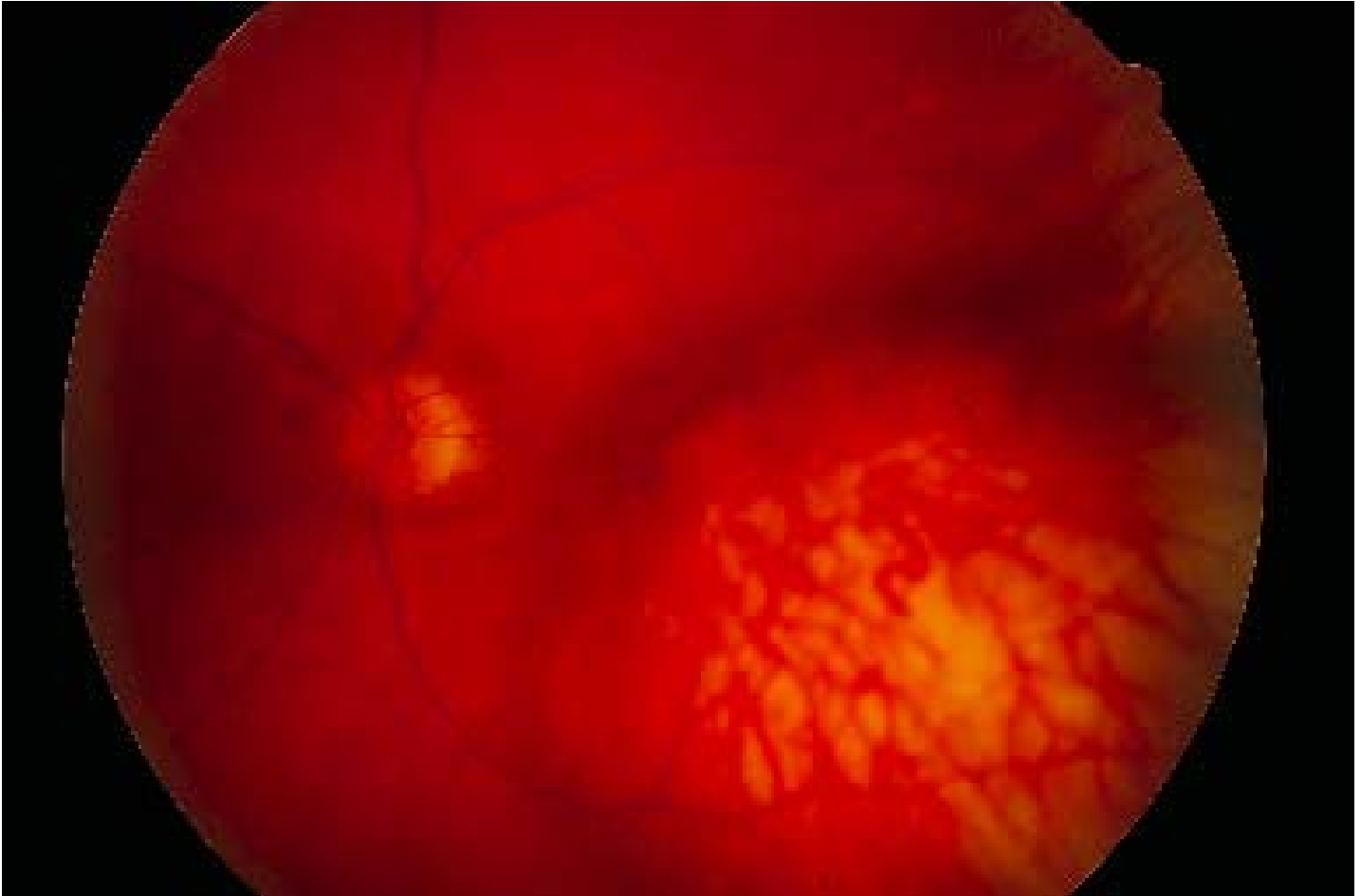
DD Aderhautmelanom: Melanozytom der Papille

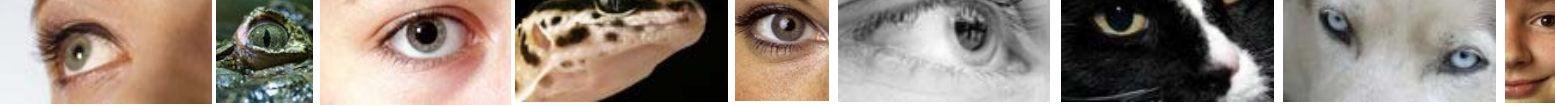


melanocytoma

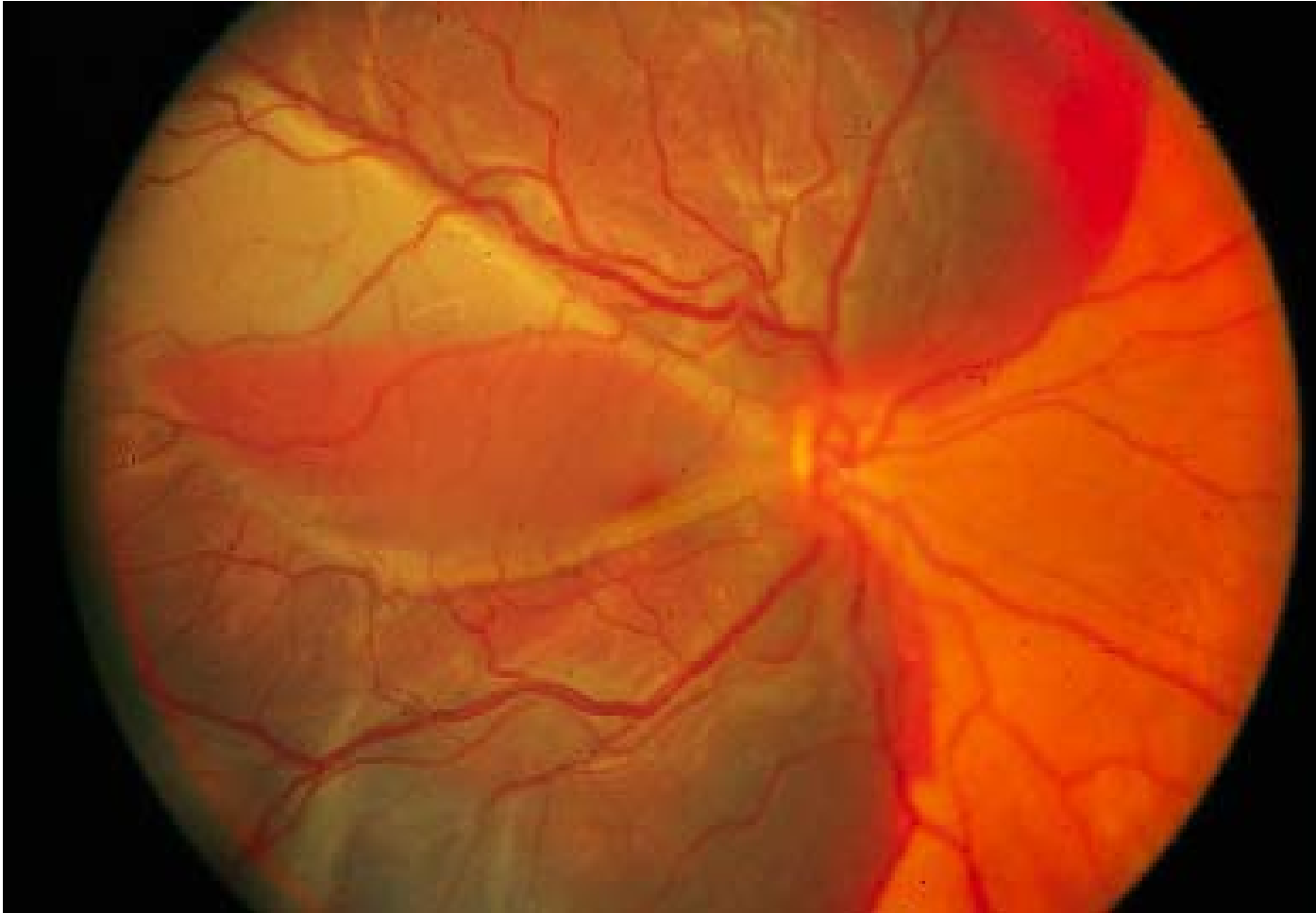


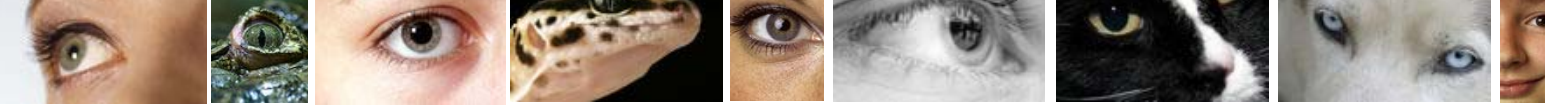
DD Aderhautmelanom: Amelanotisches Melanom



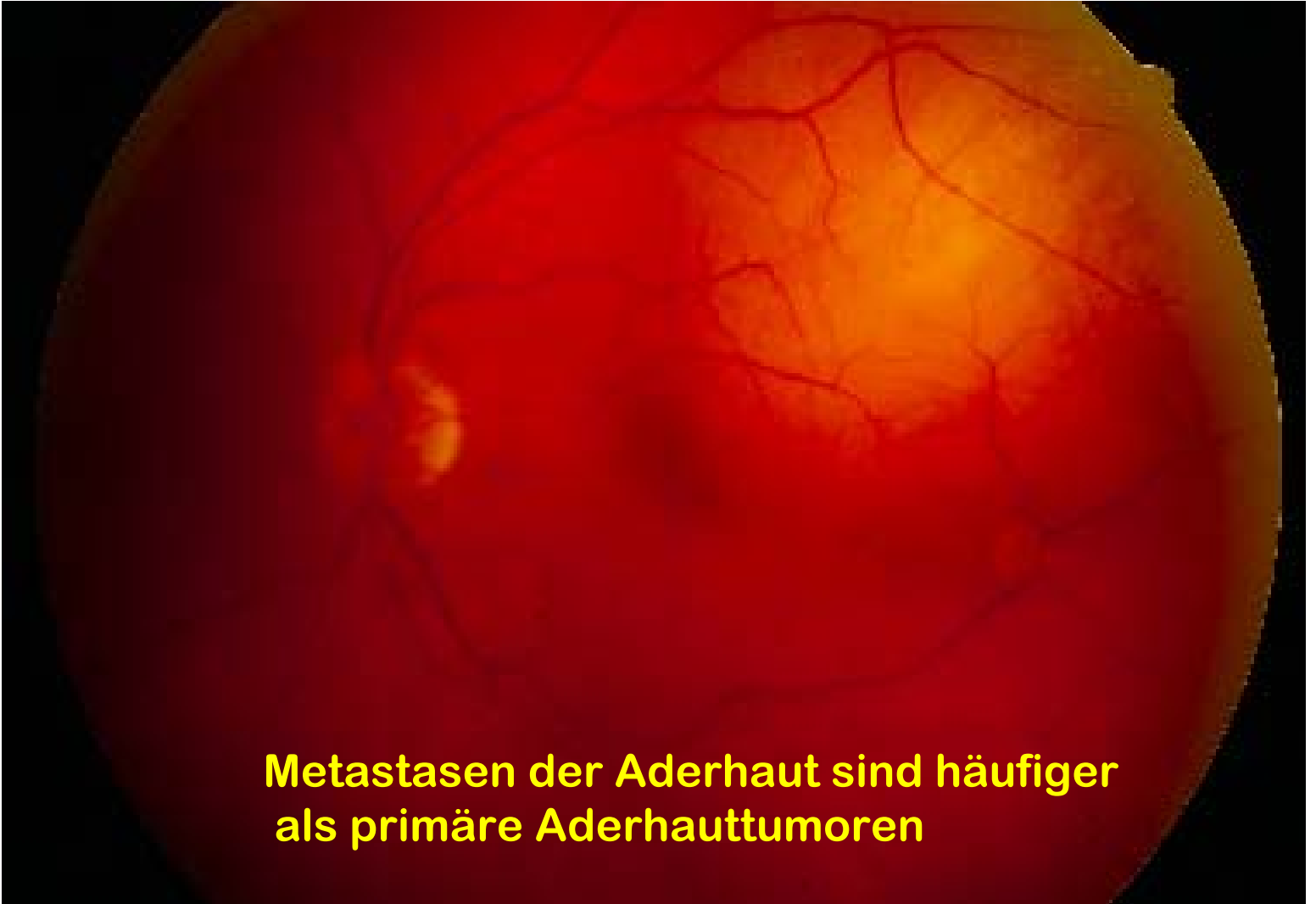

Differentialdiagnose Tumoren massive subretinale Butung, z.B. Marcumar bei AMD

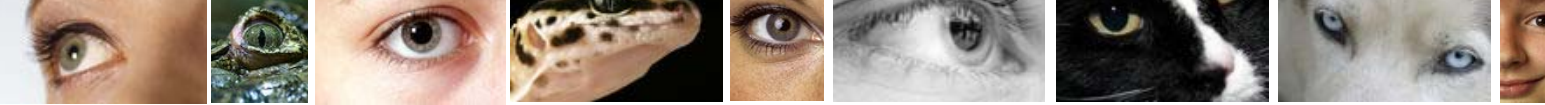




Aderhautmetastasen: Bronchialca, Mammaca, Lymphome



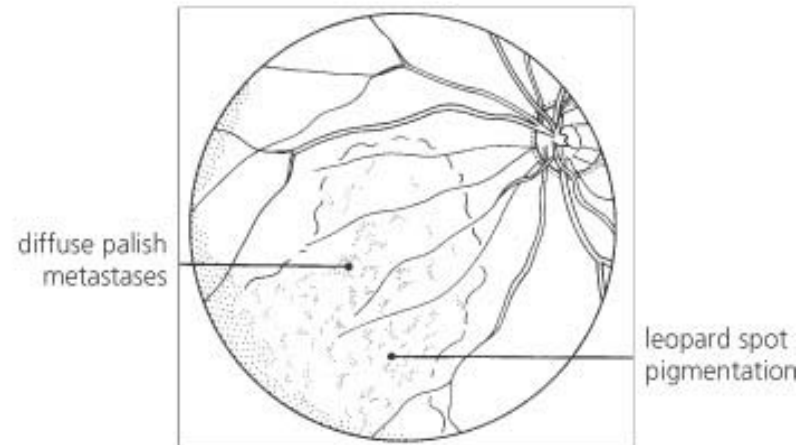
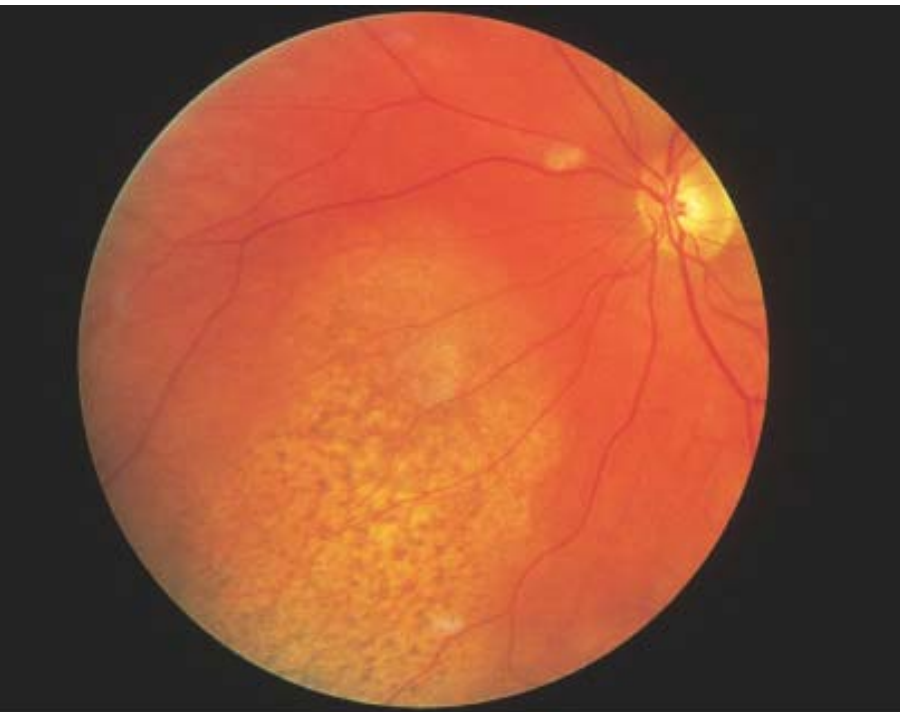**Metastasen der Aderhaut sind häufiger
als primäre Aderhauttumoren**

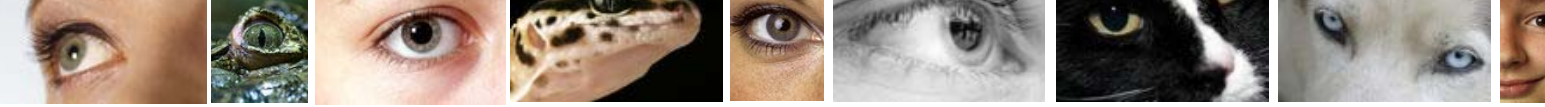


Aderhautmetastase

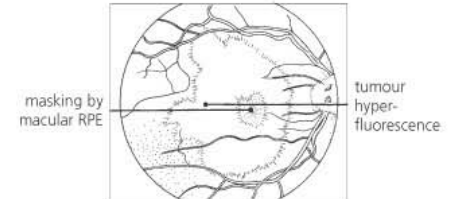
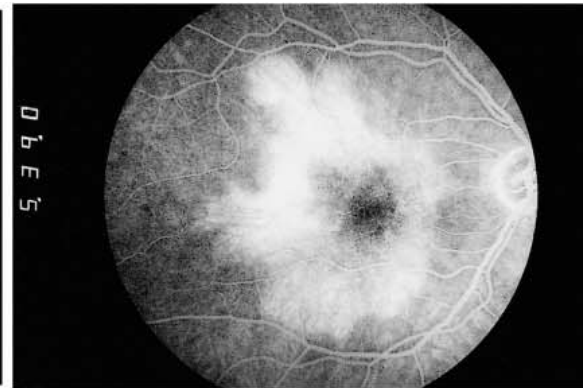
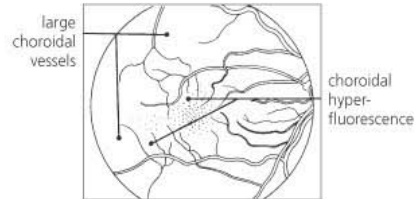
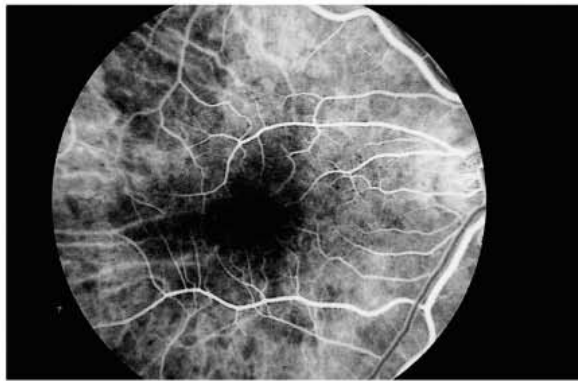
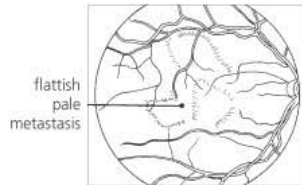
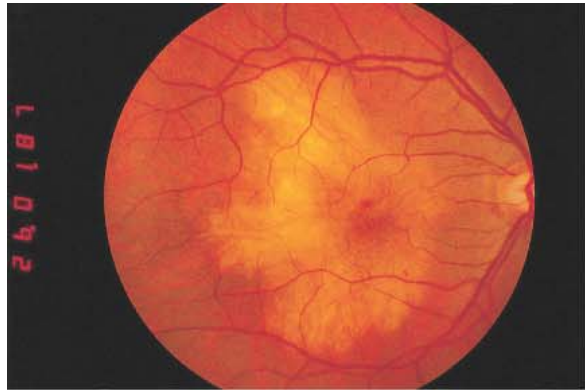
Häufigkeit maligner intraokularer Tumore:

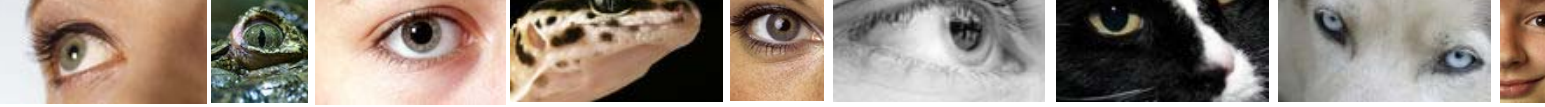
1. AH-Metastasen (10 % aller Malignome)
2. AH-Melanome



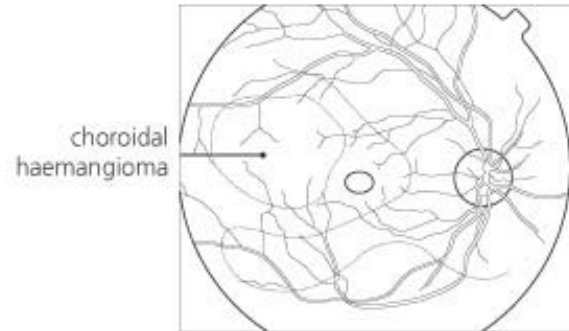
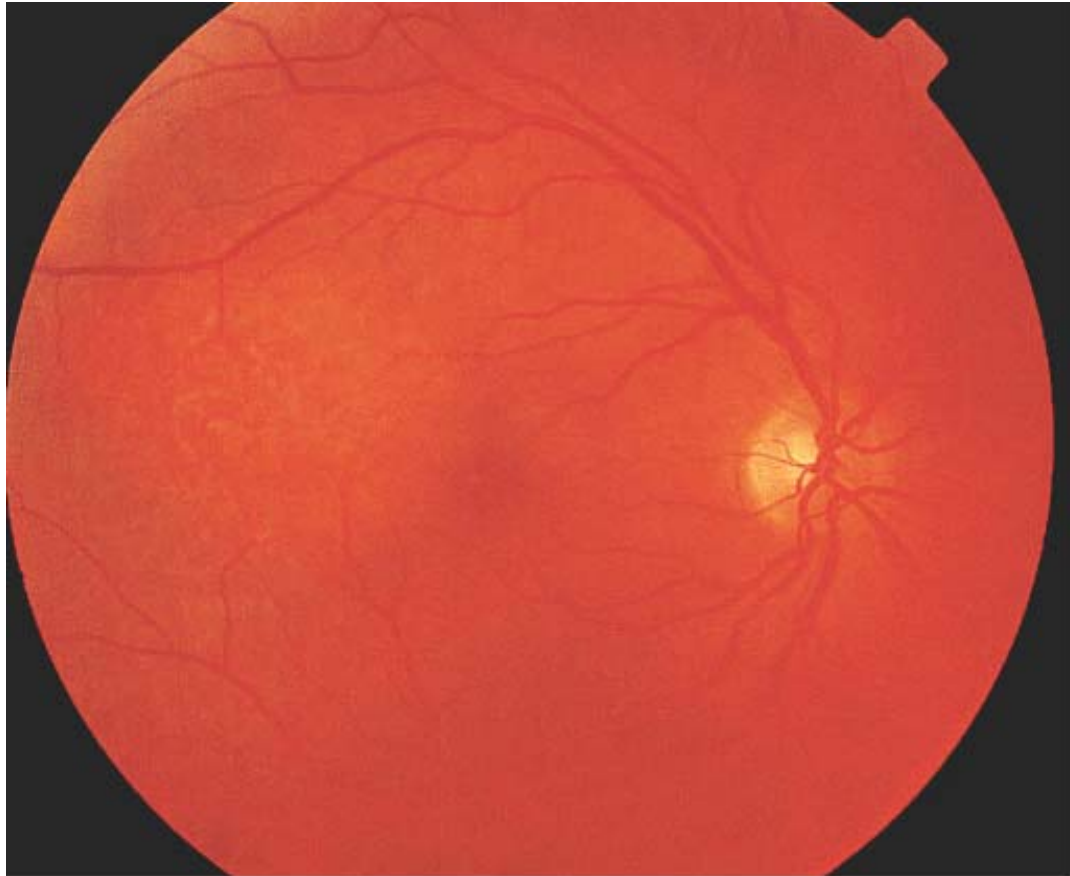


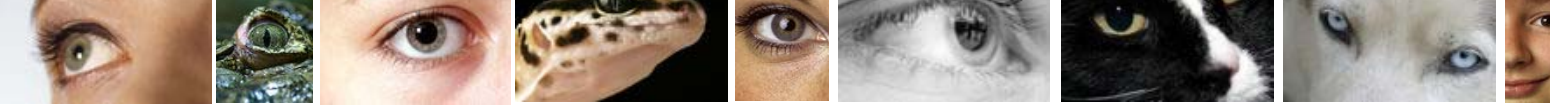
Aderhautmetastase



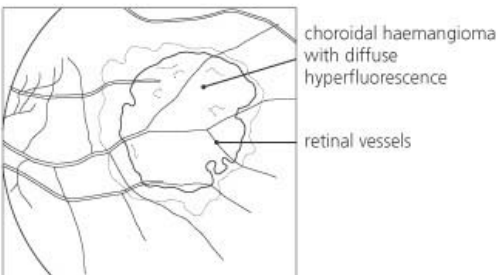
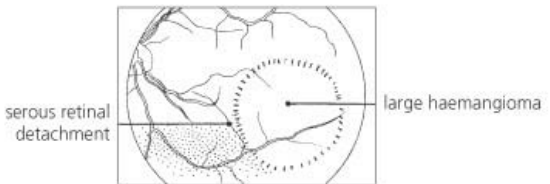
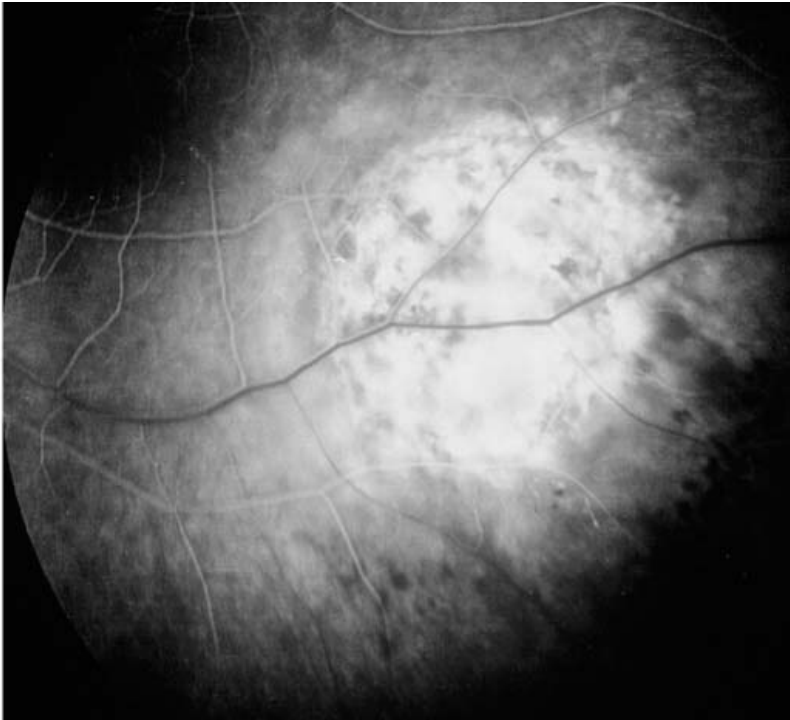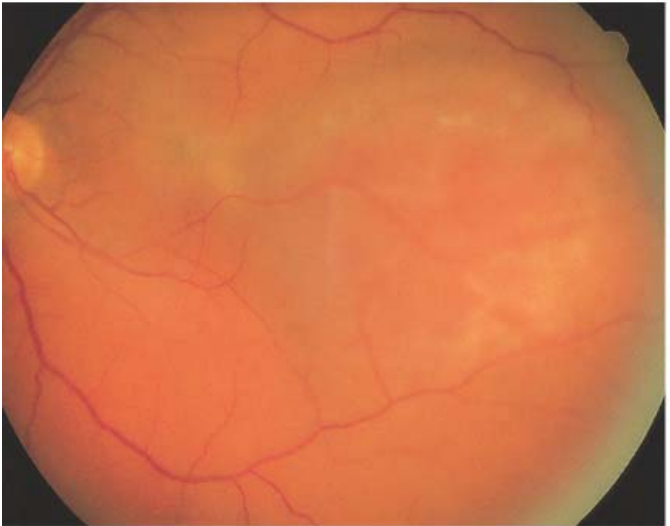


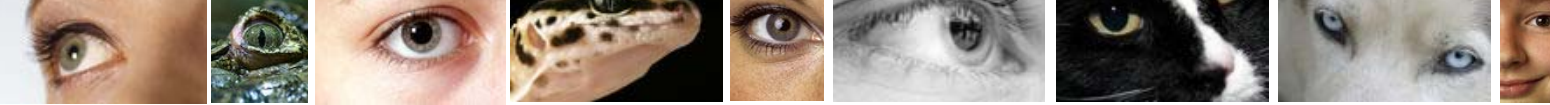
Hämangiom der Aderhaut



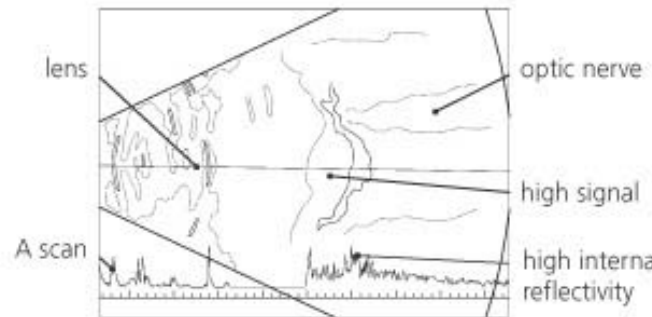
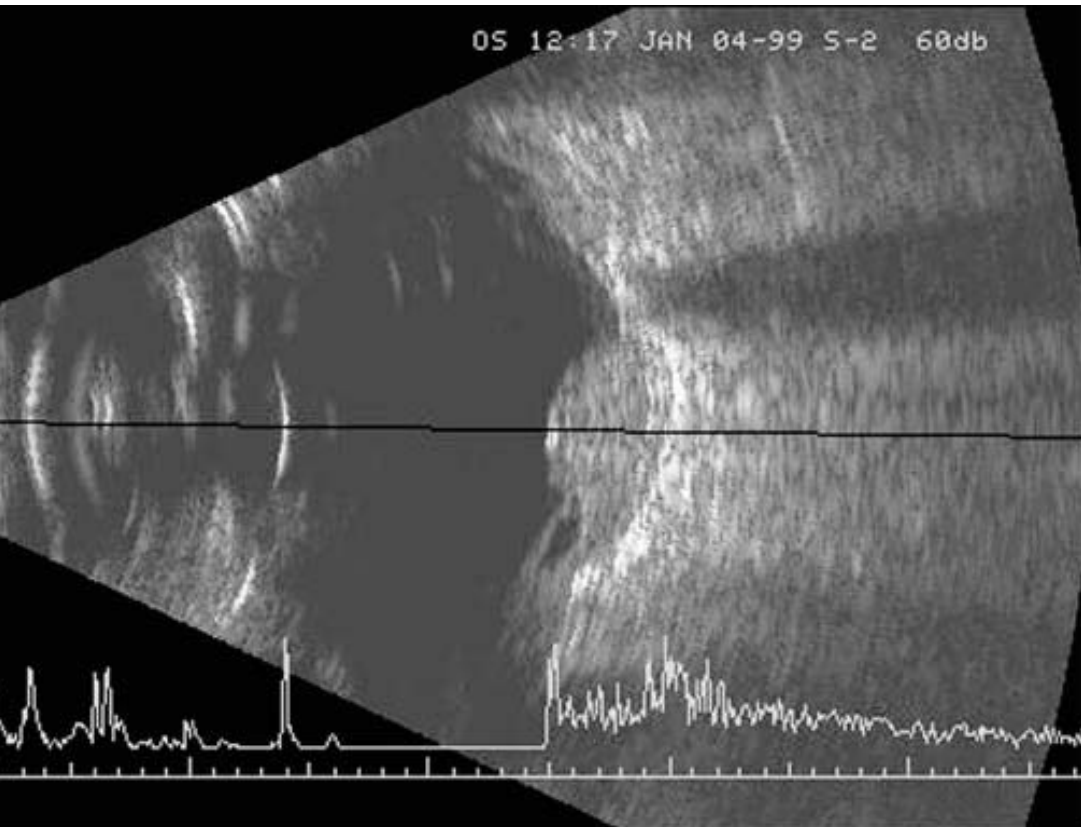


Hämangiom der Aderhaut



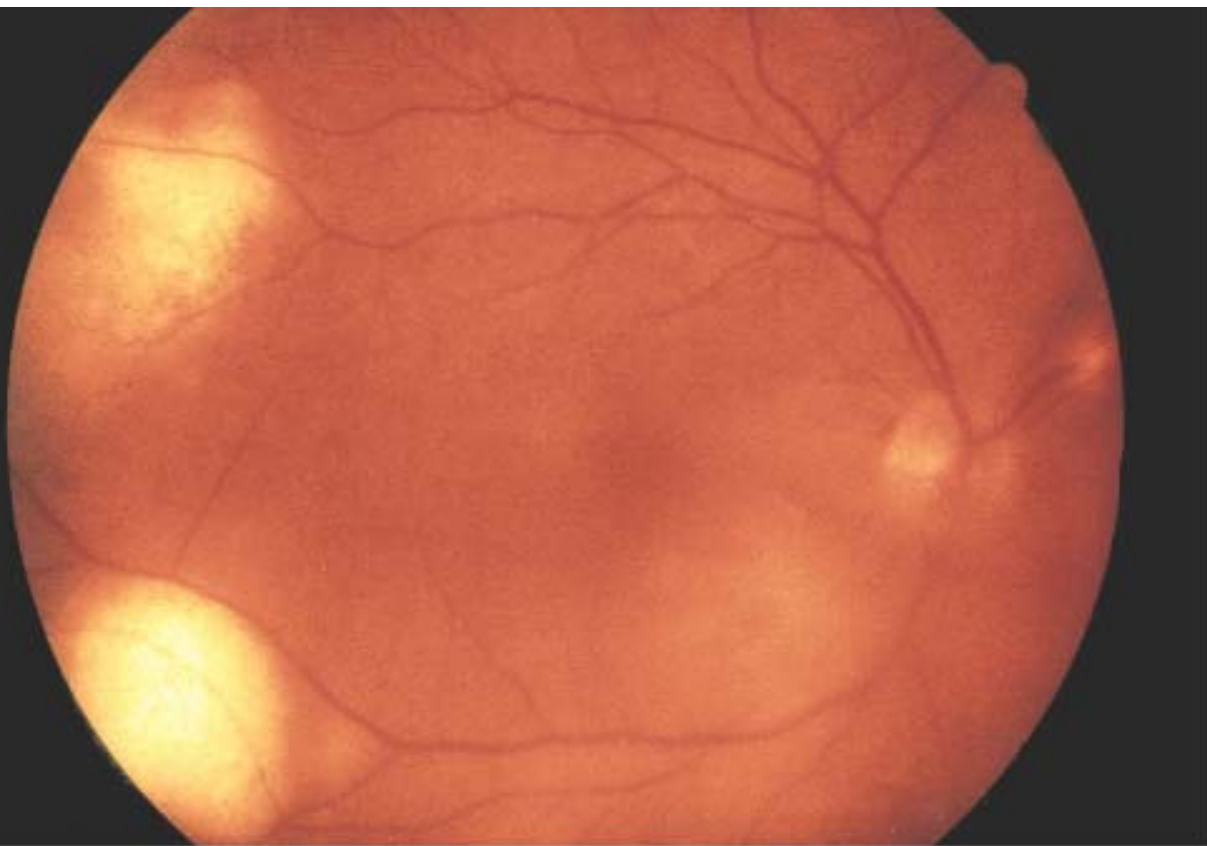

Hämangiom der Aderhaut



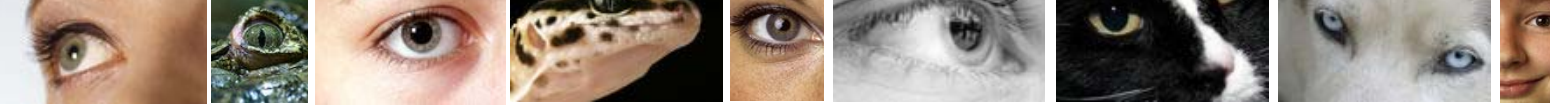


Okuläres Lymphom

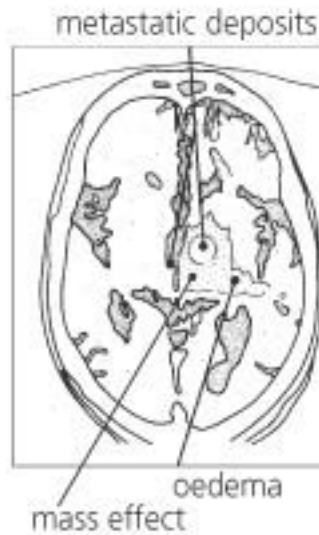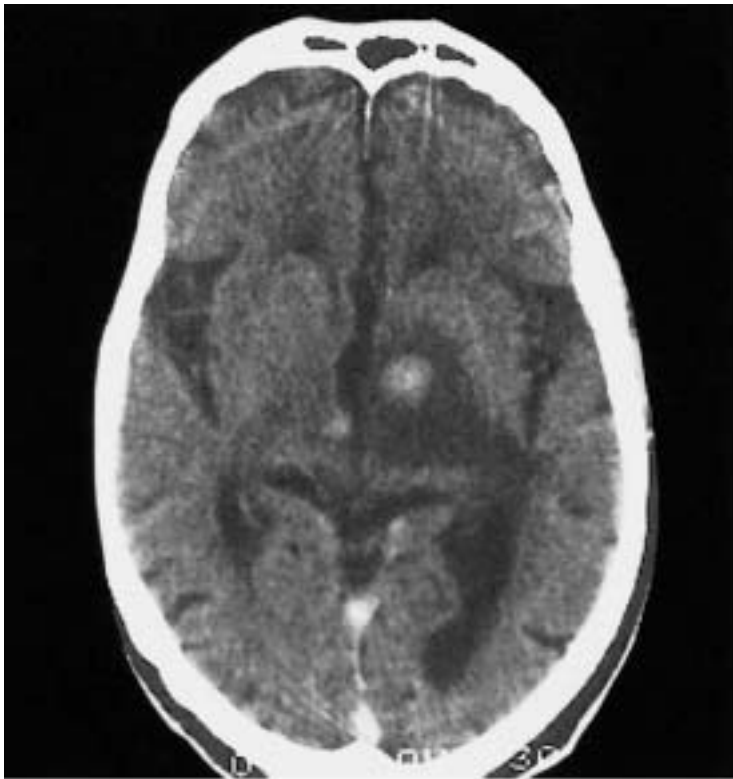


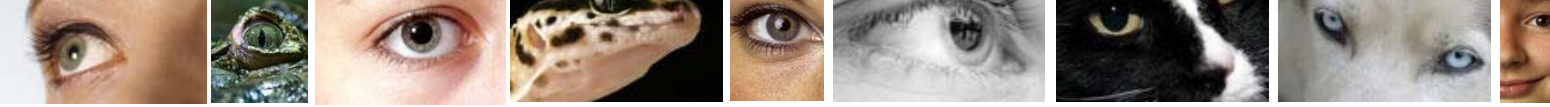
subretinal masses



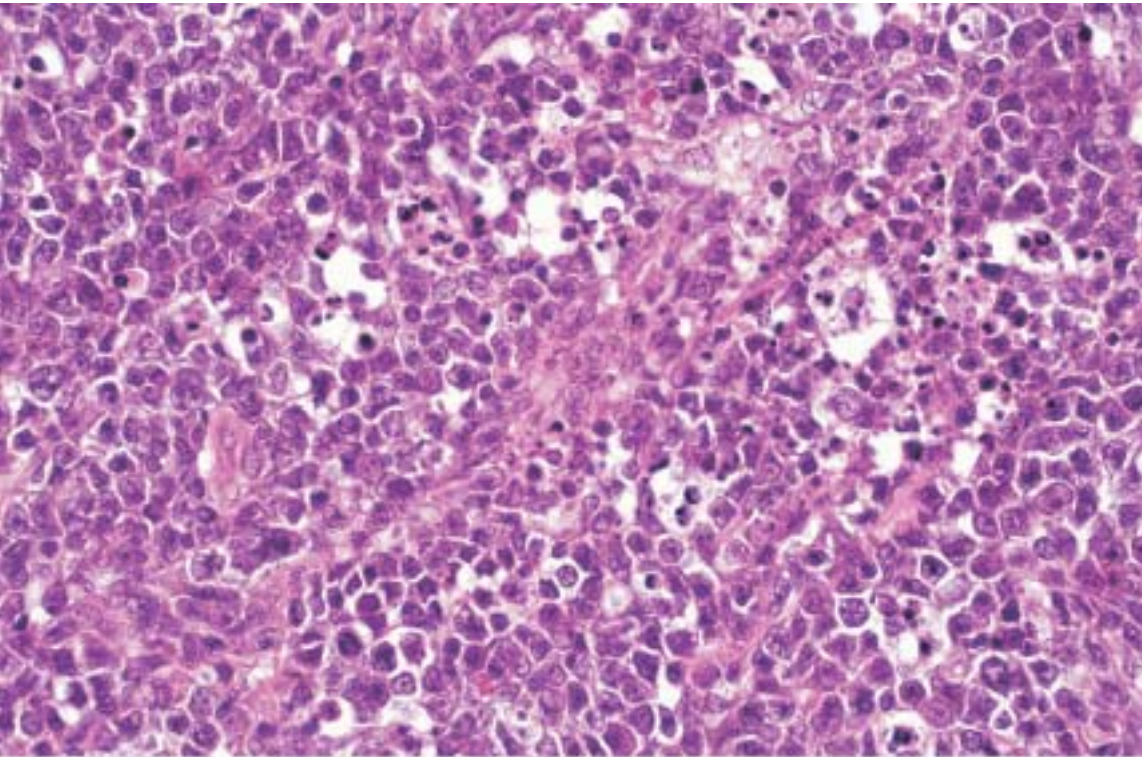


Okuläres Lymphom mit Hirnbeteiligung

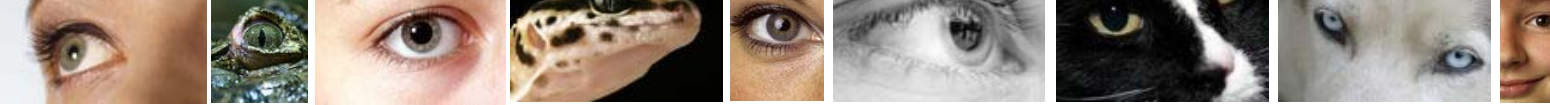




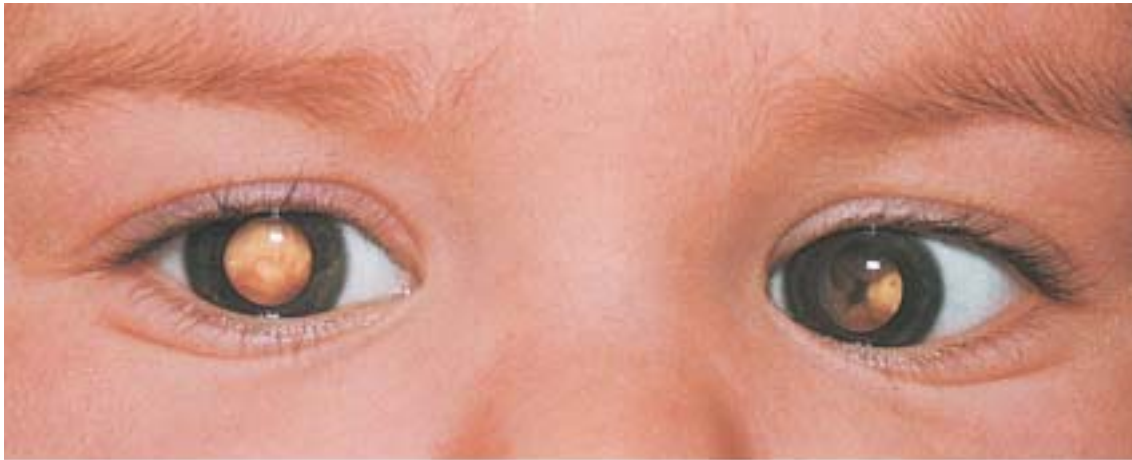Okuläres Lymphom : Histologie



© 2005 Elsevier Ltd. Spalton et al: Atlas of Clinical Ophthalmology 3e



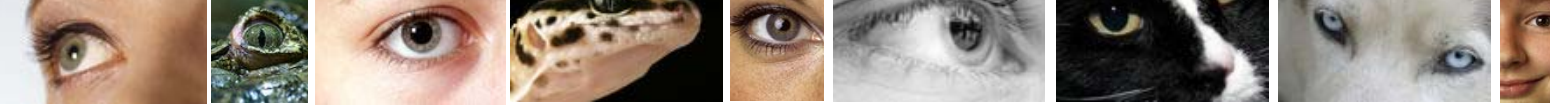
Leukokorie



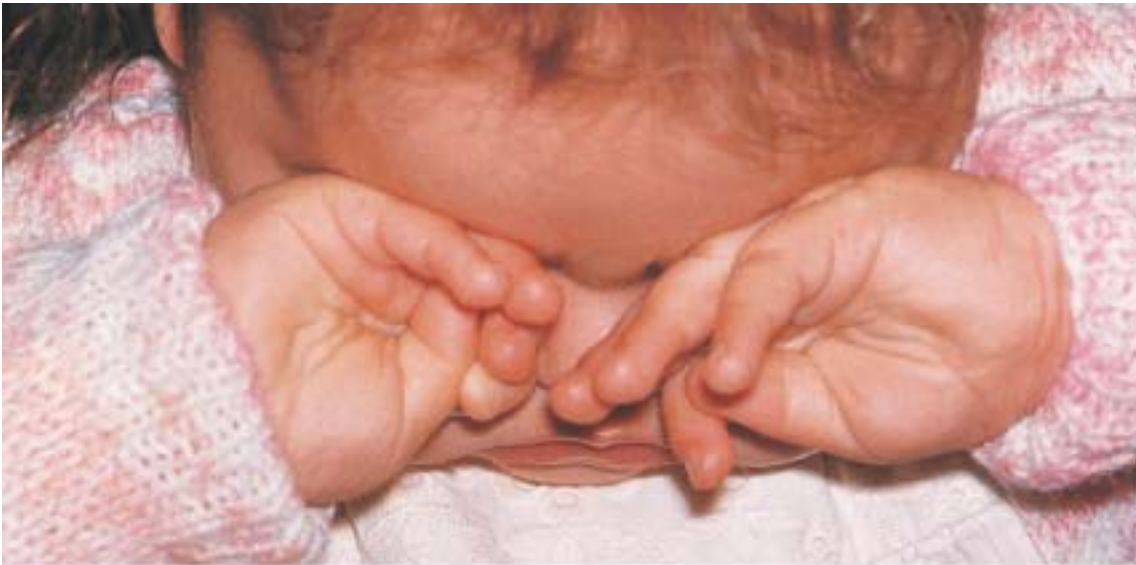© 2005 Elsevier Ltd. Spalton et al: Atlas of Clinical Ophthalmology 3e

Differentialdiagnose:

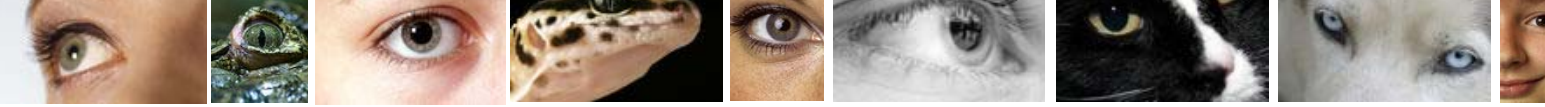
- Retinoblastom
- M. Coats
- kong. Katarakt
- PHPV / PFV Syndrom
- Uveitis
- ROP



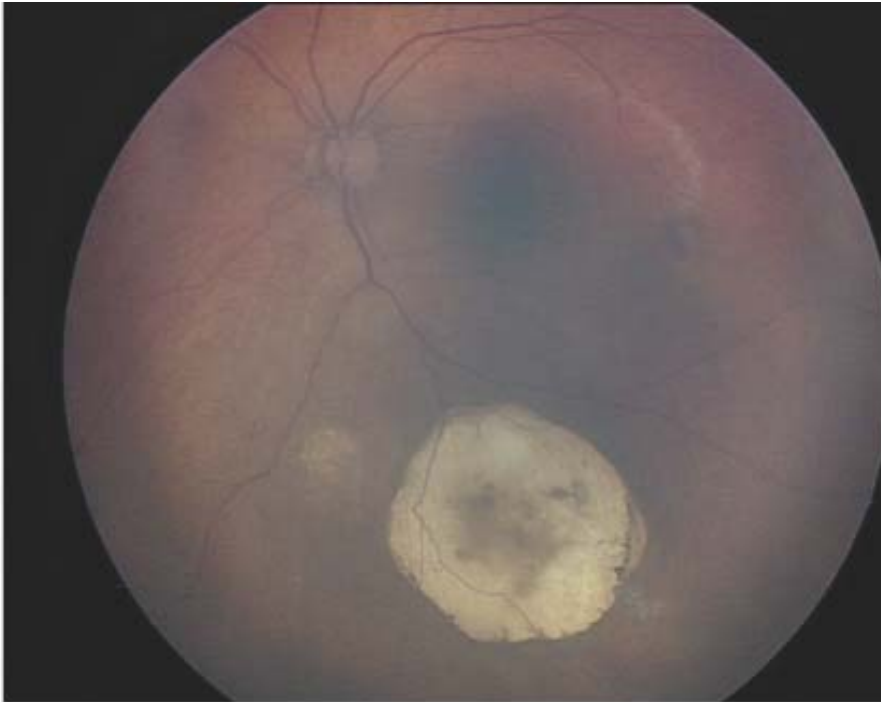
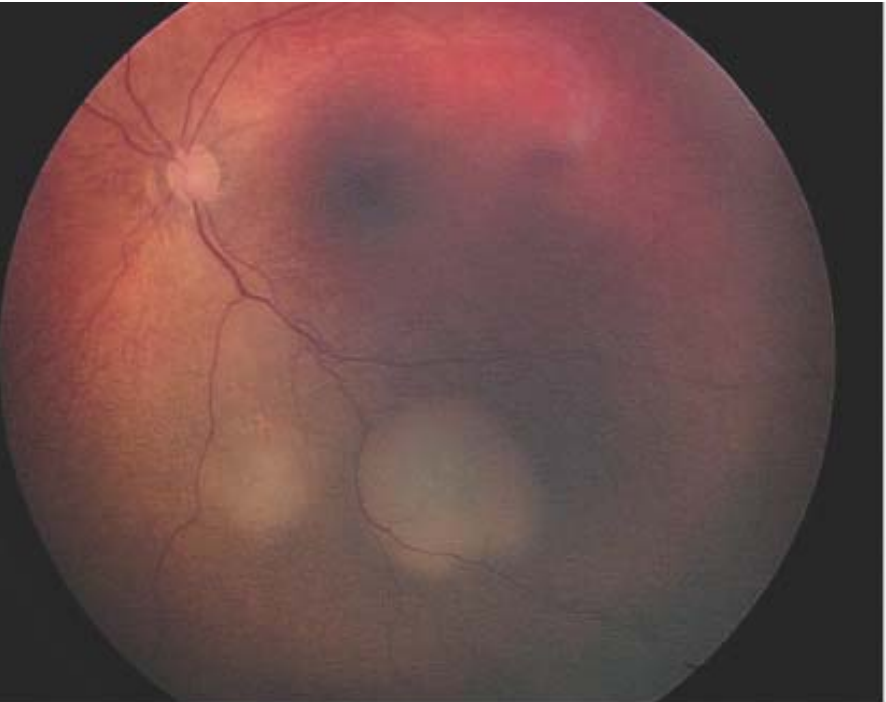
Okulodigitales Phänomen

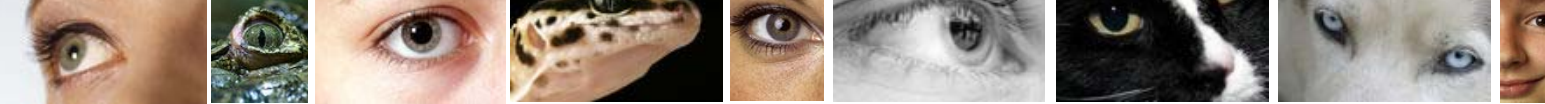


© 2005 Elsevier Ltd. Spalton et al: Atlas of Clinical Ophthalmology 3e

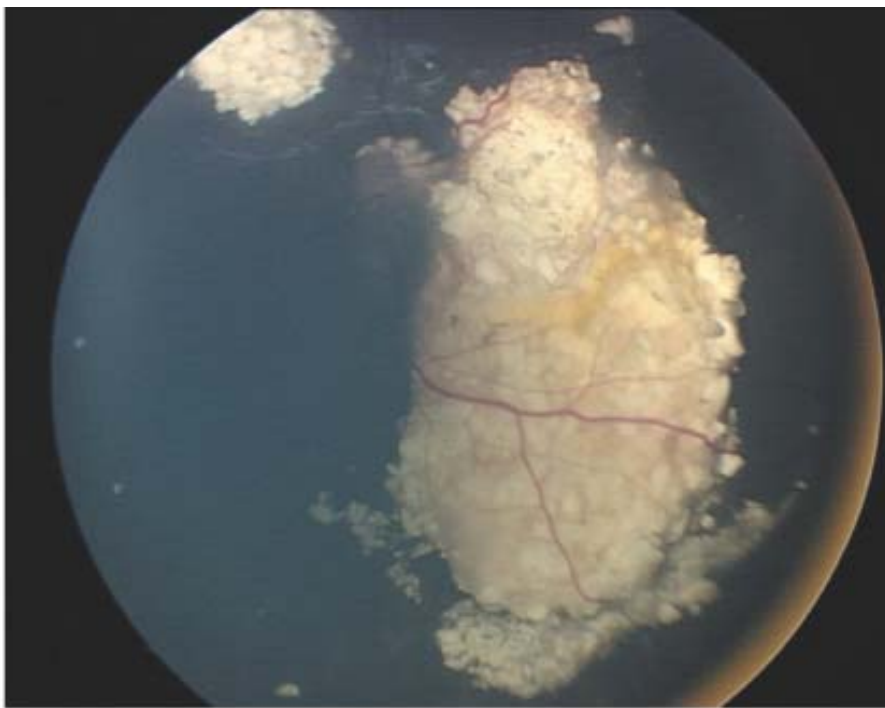
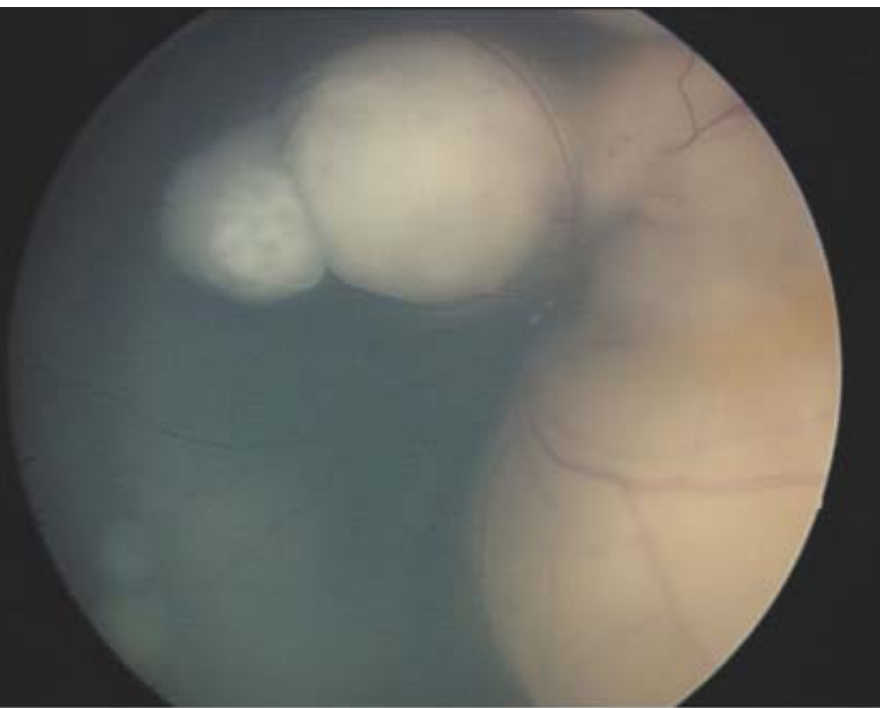


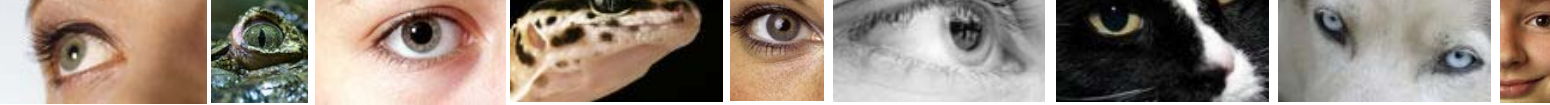
Retinoblastom: hier endophytische parazentrale Form



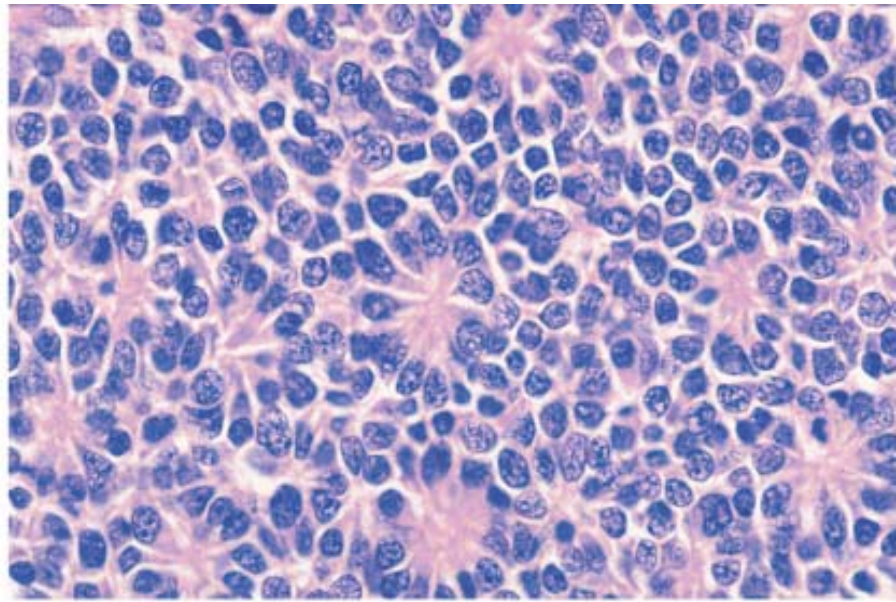
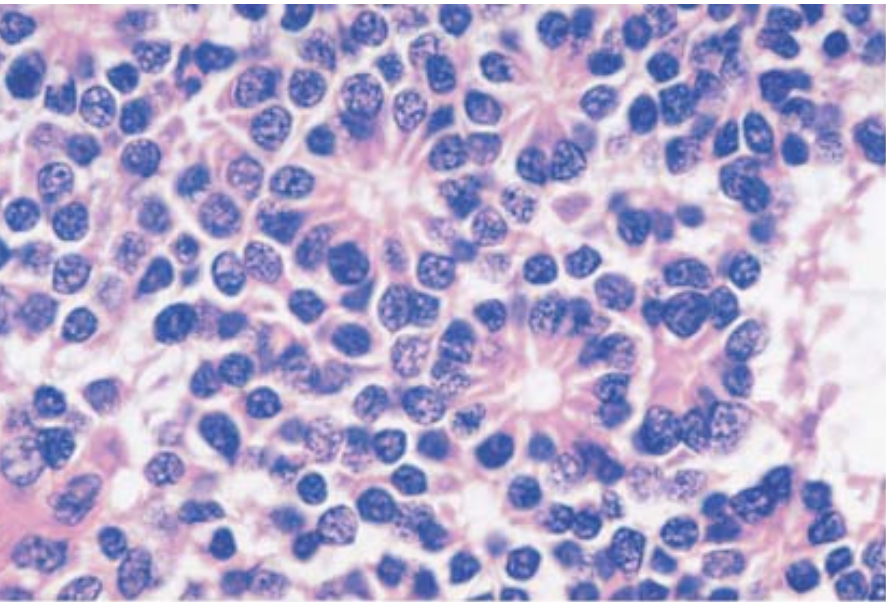


Retinoblastom: große endophytische Tumoren mit Glaskörperaussaat

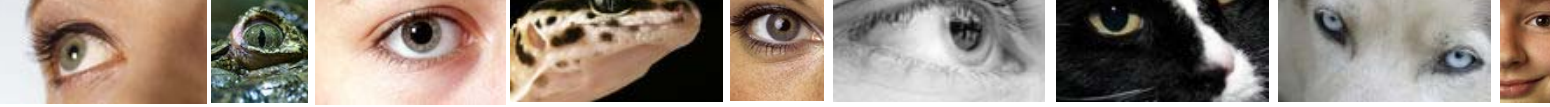




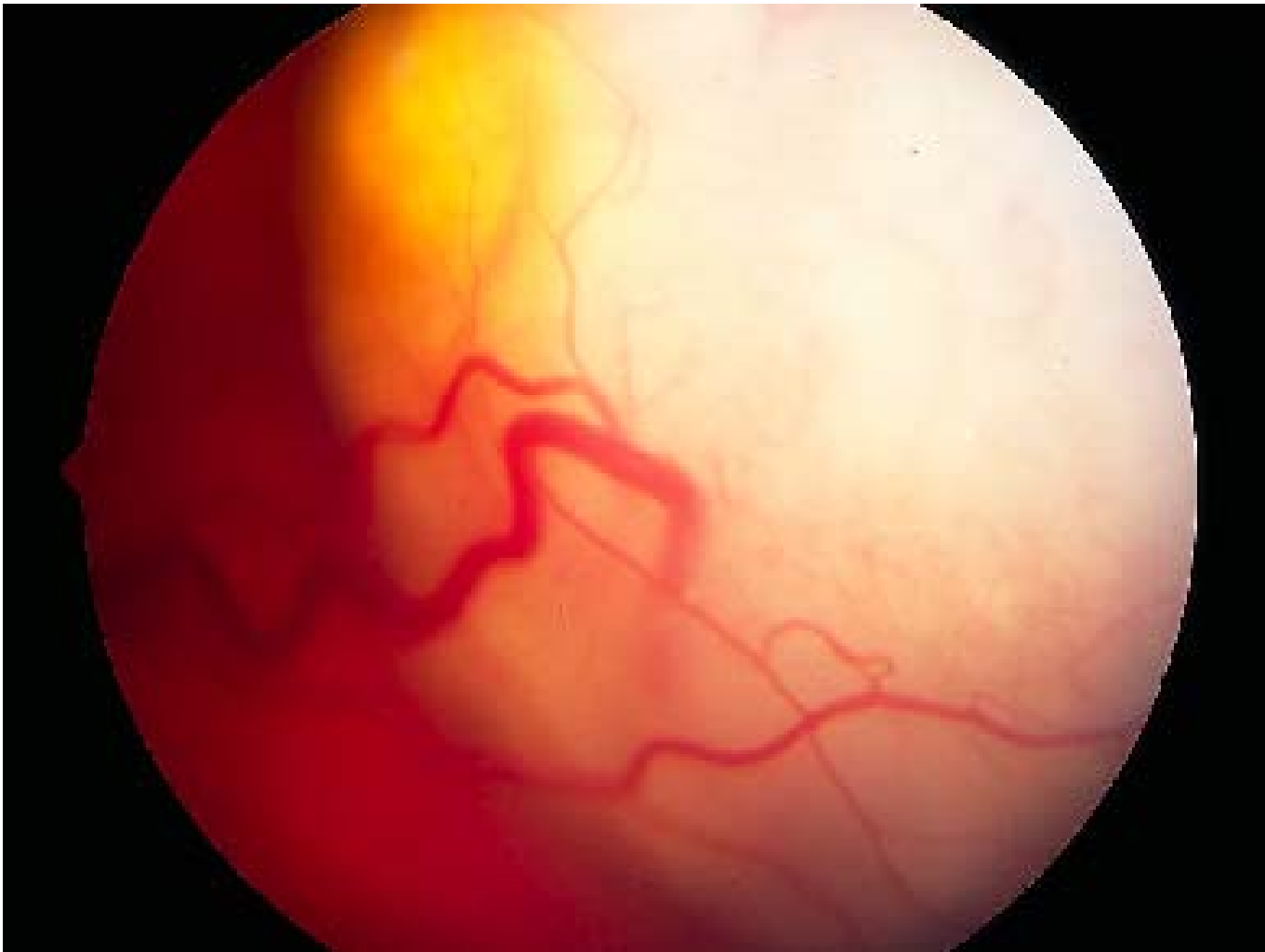Retinoblastom: Histologie – Flexner Wintersteiner Rosetten

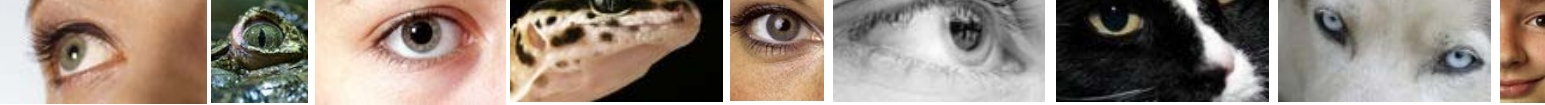


© 2005 Elsevier Ltd. Spalton et al: Atlas of Clinical Ophthalmology 3e



Retinoblastom: 1:20.000 Geburten





Retinoblastom:

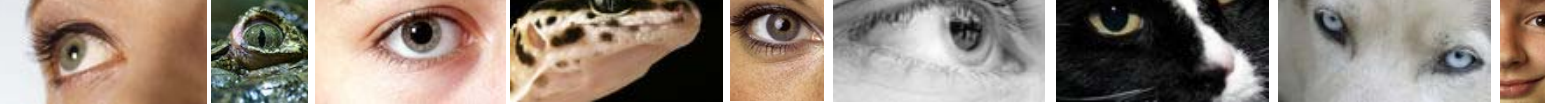
genetisch bedingter Tumor: RB1 Gen

Sporadische Form, einseitig ca. 2/3 aller Retinoblastome

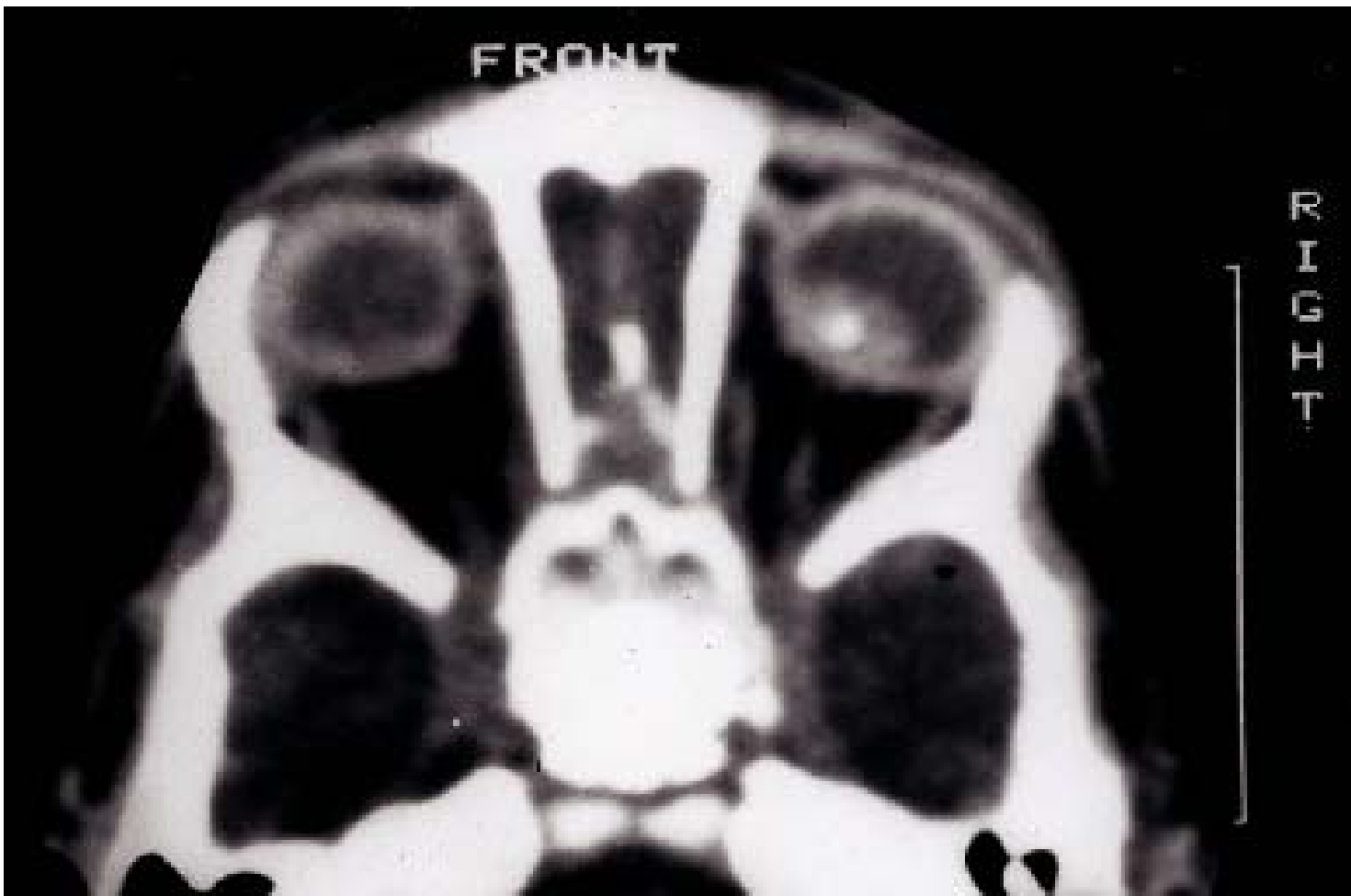
1/3 beidseitig und familiär gehäuft

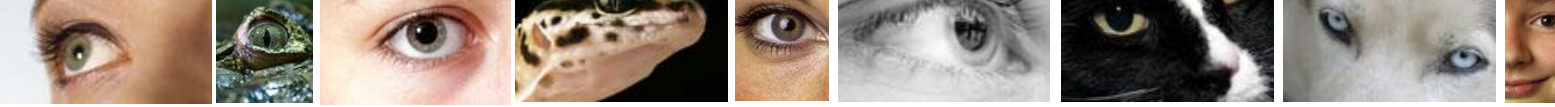
RB1 Gen liegt auf 13q14

5 Jahresüberlebensrate = 95 %

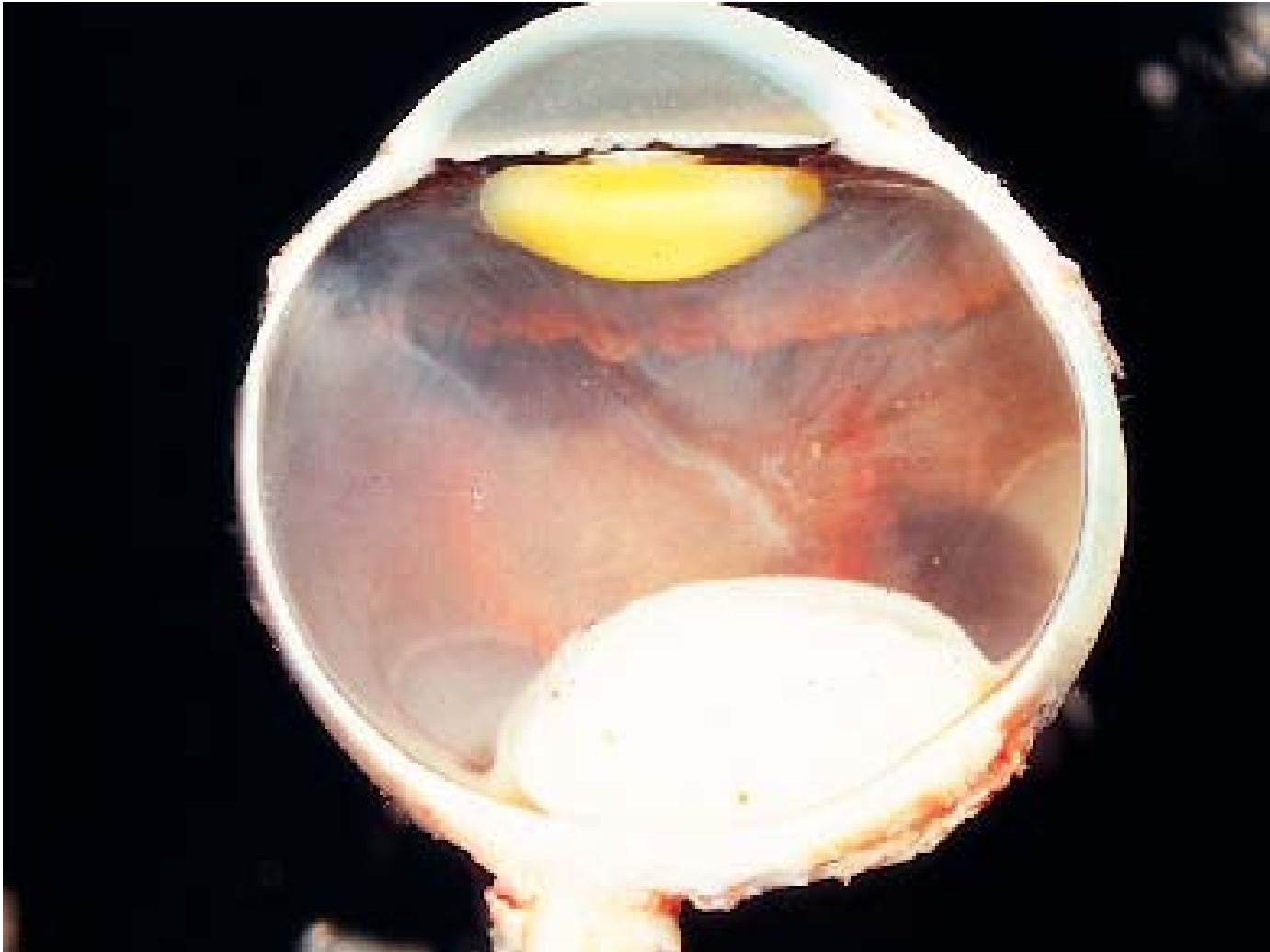


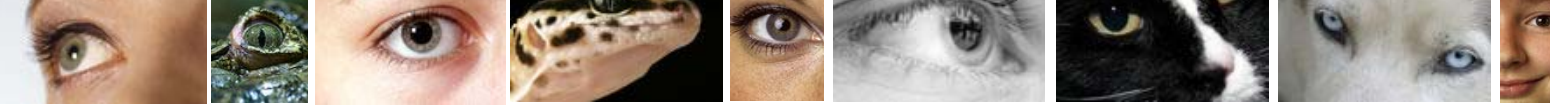
Retinoblastom: Verkalkungen im Tumor





Retinoblastom

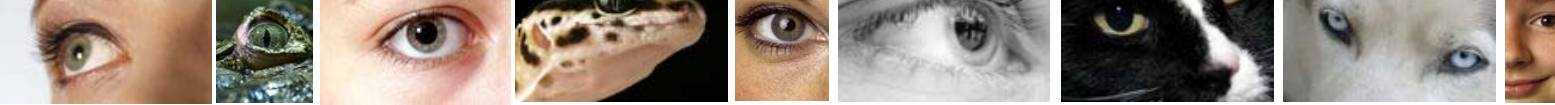




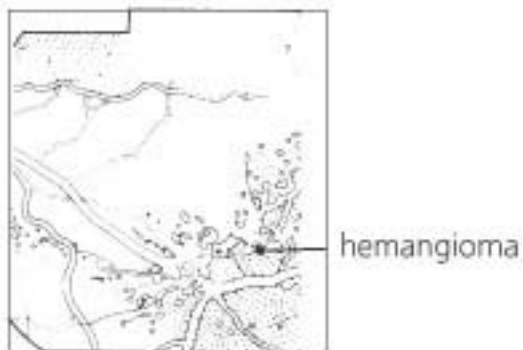
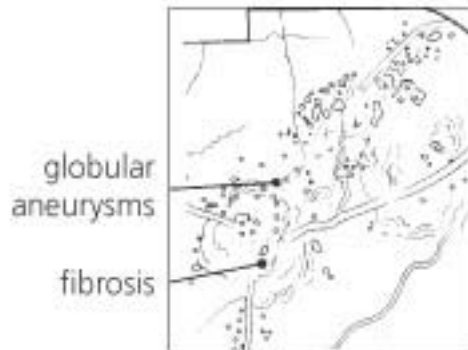
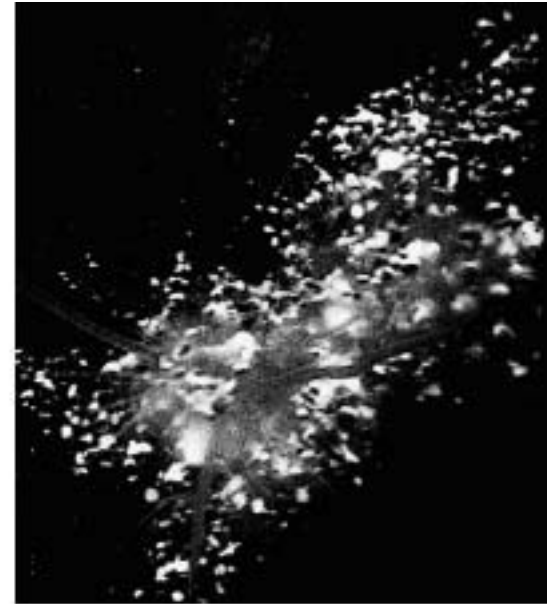
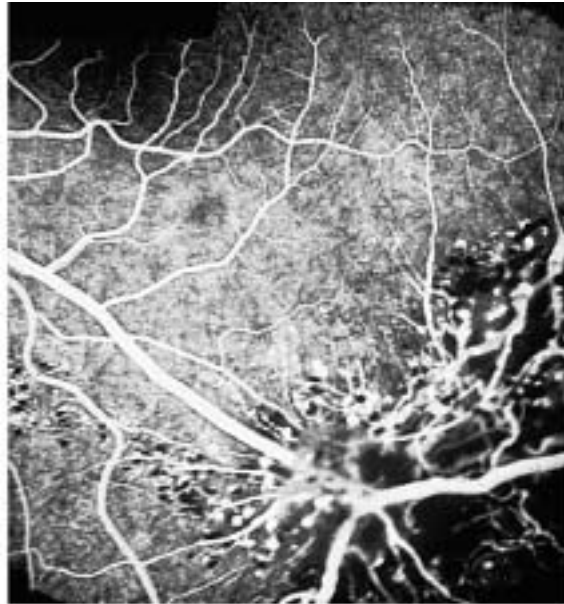
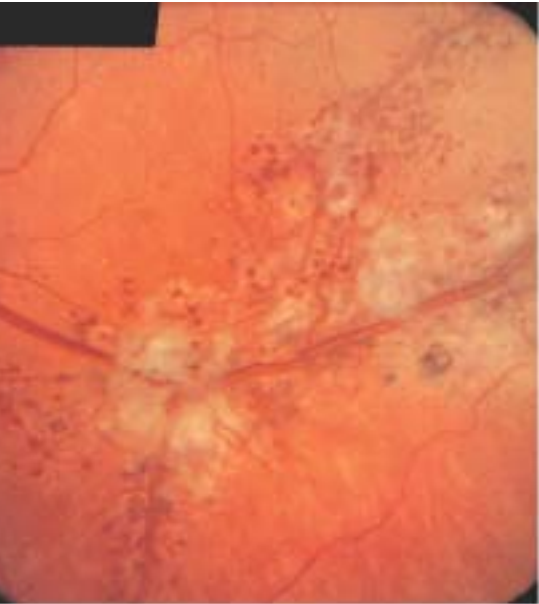
Therapieoptionen Retinoblastom

- **Enukleation (erstes Auge)**
- **Brachytherapie (Plaque)**
- **Photokoagulation**
- **Kryotherapie**
- **Systemische Chemotherapie**

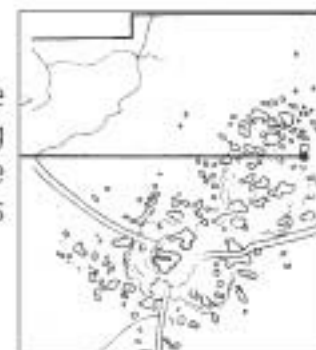
Cave Teletherapie: Zweitmalignome

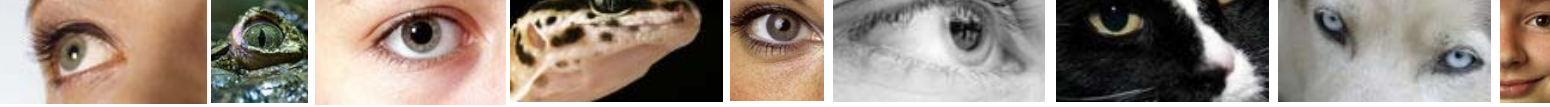


Kavernöses Hämangiom



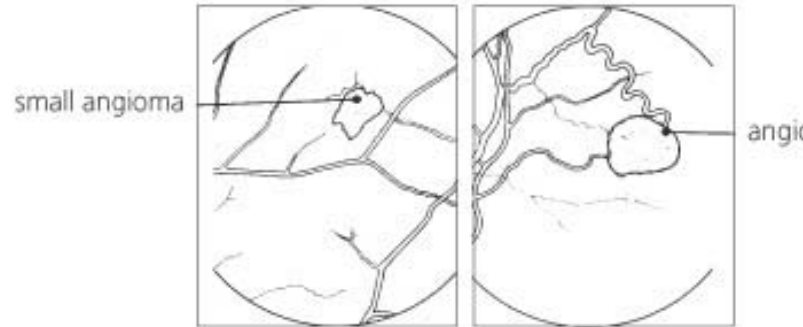
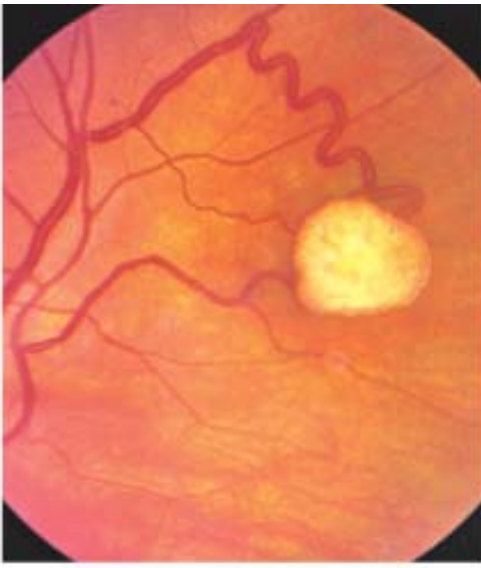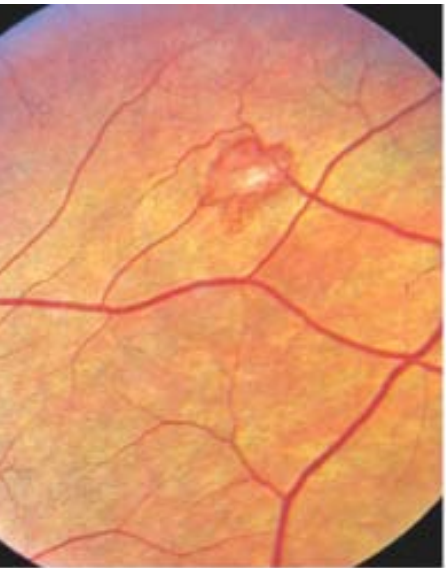late phase
angiogram showing
residual dye in the
saccular aneurysms

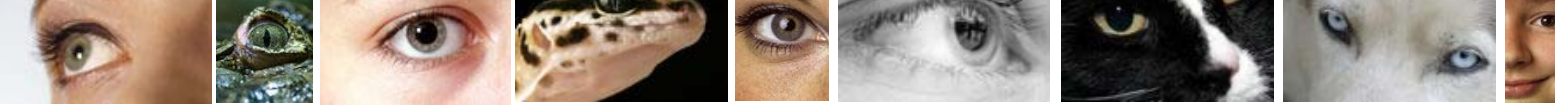




Kapilläres Hämangiom

M. von Hippel Lindau





Kapilläres Hämangiom - M. von Hippel Lindau

